

Intraventricular Administration of Cefepime for the Treatment of Meningitis due to *Pseudomonas aeruginosa*

Sameer Abdul Samad^{1*}, Hafeedha Kallarakkal², Noufal Basheer³

¹Department of Infectious Diseases, Aster Malabar Institute of Medical Sciences, Calicut, India; ²Department of Clinical Pharmacy, Aster Malabar Institute of Medical Sciences, Calicut, India; ³Department of Neurosurgery, Aster Malabar Institute of Medical Sciences, Calicut, India

ARTICLE INFO

Letter to the Editor

Keywords: Intraventricular, Cefepime, *Pseudomonas*

Received: 14 Dec. 2022

Received in revised form: 20 Feb. 2023

Accepted: 28 Feb. 2023

DOI: 10.52547/JoMMID.11.1.60

*Correspondence

Email: sameerinvogue@gmail.com

Tel: + 918800763364

Fax: + 918800763364

© The Author(s)



To the editor:

Beta-lactam antibiotics are traditionally not considered for intrathecal therapy, despite their poor penetration into the cerebrospinal fluid (CSF) during intravenous therapy, because target concentrations of the beta-lactam antibiotic in the central nervous system can usually be achieved with a higher intravenous dose [1]. However, in cases where inadequate clinical response is seen even with maximal doses of intravenous antibiotics, and when access for intraventricular administration of antibiotics is available, this route can be utilized for patient management, as we report now. Cefepime at high doses has been reported to cause seizures and encephalopathy [2]. However, therapeutic intraventricular administration of cefepime for the management of nosocomial meningitis, leading to successful microbiological clearance has not been reported previously in the literature.

A nine-month-old baby diagnosed with Kawasaki disease developed subarachnoid and intraventricular hemorrhage due to the rupture of a V4 segment aneurysm of the right vertebral artery, which was coiled via femoral access. She also developed dissection of bilateral internal

carotid arteries causing extensive cerebral infarcts and cerebral venous sinus thrombosis affecting- the superior sagittal, right transverse, and sigmoid sinuses. Continuous extra ventricular drainage (EVD) for CSF was done because of non-communicating hydrocephalus (Fig. 1). She developed lower respiratory tract infection and meningitis due to carbapenem-resistant *Pseudomonas aeruginosa*, which was sensitive to cefepime with a minimum inhibitory concentration (MIC) of 0.5 µg/ml.

She was started on intravenous (IV) cefepime at the maximal dose of 50 mg/kg of body weight given three times a day, each amount given by extended infusion over three hours. We decided to continue the treatment with IV cefepime for two more weeks from the time point when her CSF culture becomes sterile. However, her CSF culture repeated after ten days of starting intravenous cefepime still grew *P. aeruginosa* with an increase in the MIC of cefepime to 8 µg/ml. It was suspected that cefepime did not achieve adequate bactericidal levels in the CSF due to continuous CSF drainage in place.

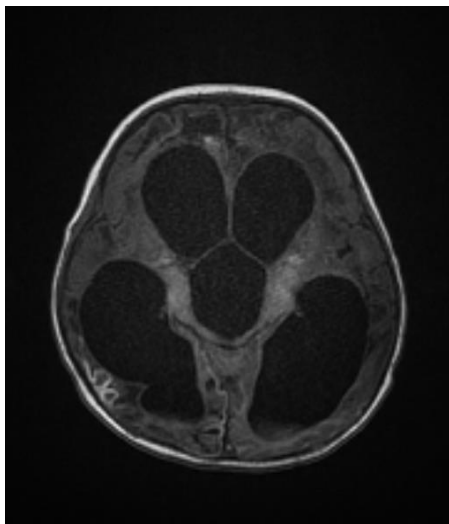


Fig. 1. Magnetic resonance imaging of the brain showing obstructive hydrocephalus (transverse view)

The continuous EVD was later changed to intermittent CSF tapping from an Ommaya reservoir. After 14 days of starting IV cefepime, CSF culture again grew *P. aeruginosa* with a MIC of 0.5 µg/ml, identified using a commercial kit (VITEK® 2 bioMérieux). Cefepime is a zwitterion that is highly hydrophilic and poorly lipid soluble. Intravenous cefepime in children at a dose of 50 mg/kg every eight hours achieves a serum concentration of about 4-8 µg/ml [3]. With a typical CSF/serum concentration ratio of 10% for cefepime, it was assumed that cefepime might not achieve adequate levels in CSF [4]. We decided to give intraventricular cefepime at a dose that did not reach the toxic levels in CSF reported previously in the literature, i.e., 6-18 mg/L [5]. The amount for intraventricular administration was calculated for a CSF volume of 20 ml and a target drug level of 5 times the MIC, which was 0.05 mg of cefepime in 0.5 ml of 5% dextrose. The cefepime preparation contained L-arginine as the excipient. After 25 days of IV cefepime and six days of intraventricular cefepime, the CSF culture became sterile.

The child was already on dual anti-epileptic drugs, phenytoin and levetiracetam when she developed meningitis due to *P. aeruginosa*. Her Glasgow coma scale (GCS) score remained similar before and after giving intraventricular cefepime, and she did not develop any tonic or clonic seizures during therapy with intraventricular cefepime.

The intraventricular route of administration of cefepime can be utilized as an adjunct to intravenous therapy of meningitis caused by organisms like *P. aeruginosa*. This needs to be evaluated in observational studies and clinical trials.

ACKNOWLEDGMENT

We thank the microbiologist Dr. Reshmi Gopalakrishnan for providing the microbiological reports and all the doctors and staff involved in caring for the patient. No specific funding was received from any agency.

CONFLICT OF INTEREST

The authors declare that there are no conflicts of interest associated with this manuscript.

REFERENCES

1. Nau R, Sorgel F, Eiffert H. Penetration of drugs through the blood-cerebrospinal fluid/blood-brain barrier for treatment of central nervous system infections. *Clin Microbiol Rev.* 2010; 23 (4): 858-83.
2. Reza M, Bagert B, Reese G, Reeves MA. Cefepime-induced Neurotoxicity in the Critically Ill: A Modifiable Risk Factor (P7-12.001). *Neurology.* 2022; 98 (18 Supplement).
3. Pacifici GM, Marchini G. Clinical Pharmacology of Cefepime in Infants and Children. *Int J Pediatr.* 2017; 5 (4): 4723-40.
4. Durand-Maugard C, Lemaire-Hurtel AS, Gras-Champel V, Hary L, Maizel J, Prud'homme-Bernardy A, et al. Blood and CSF monitoring of cefepime-induced neurotoxicity: nine case reports. *J Antimicrob Chemother.* 2012; 67 (5): 1297-9.
5. Payne LE, Gagnon DJ, Riker RR, Seder DB, Glisic EK, Morris JG, et al. Cefepime-induced neurotoxicity: a systematic review. *Crit Care.* 2017; 21 (1): 276.

Cite this article:

Abdul Samad S, Kallarackal H, Basheer N. Intraventricular Administration of Cefepime for the Treatment of Meningitis due to *Pseudomonas aeruginosa*. *J Med Microbiol Infect Dis*, 2023; 11 (1): 60-61. DOI: 10.52547/JoMMID.11.1.60