

## Imported Malaria in an Immigrant Toddler Boy in Kashan, a Non-Malaria Endemic Area, Central Iran

Tayebeh Taghipour<sup>1</sup>, Mahzad Erami<sup>2</sup>, Mojtaba Fakhrei<sup>2</sup>, Hossein Hooshyar<sup>1\*</sup>

<sup>1</sup>Department of Medical Parasitology, Kashan University of Medical Sciences, Kashan, Iran; <sup>2</sup>Shahid Beheshti Hospital, Kashan University of Medical Sciences, Kashan, Iran

### ARTICLE INFO

#### Case Report

**Keywords:** Malaria, Plasmodium, Imported, Kashan, Children

Received: 27 Jun. 2022

Received in revised form: 27 Jul. 2022

Accepted: 02 Aug. 2022

DOI: 10.52547/JomMID.10.3.149

#### \*Correspondence

**Email:** hooshyar4@yahoo.com

**Tel:** +983155540021

**Fax:** +983155541112

© The Author(s)



### ABSTRACT

Malaria is an imported disease in non-endemic regions of Iran. Imported malaria cases to Iran mostly come from illegal immigrants from neighboring eastern countries. The present study describes a case of imported malaria in a 14-month-old Afghan boy with prolonged fever, vomiting, and diarrhea. He was referred and hospitalized in Shahid Beheshti, Kashan, central Iran, in December 2021. He and his parents traveled and immigrated to Kashan, Iran, three weeks before hospitalization. After staining with Giemsa stain, a thin blood smear test showed *Plasmodium vivax* with the Schüffner's dots in red blood cells. The patient was treated with an antimalarial drug and discharged from the hospital with normal vital signs. Before arriving in Iran, all immigrants should receive a screening test or be checked for malaria symptoms.

### INTRODUCTION

Malaria is considered one of the most important vector-borne diseases [1], often transmitted through the bites of *Anopheles* mosquitoes. It is the most important parasitic disease worldwide, especially in tropical and subtropical regions [2]. According to the WHO 2021 world malaria report, there were an estimated 241 million malaria cases and 627 000 malaria deaths globally in 2020 [1]; most deaths occur in children under five years of age [3].

Malaria is caused by protozoan parasites belonging to the genus *Plasmodium*. Under natural conditions, five species of parasite can infect humans, including, *Plasmodium falciparum*, *Plasmodium vivax*, *Plasmodium ovale*, *Plasmodium malariae*, and *Plasmodium knowlesi*. Among these species, *P. vivax* is the most common type, but *P. falciparum* is the most severe and fatal species worldwide. *P. knowlesi* is the cause of zoonotic malaria and is widely prevalent in South East Asia [2, 3].

In Iran, *P. vivax* and *P. falciparum* are now the prevalent *Plasmodium* species, and *P. malariae* is rare [4]. Sistan and Balochistan, Hormozgan, and Kerman provinces in the south and southeast of Iran are

endemic malaria zones with very low incidence in recent years [5]. In 2009, Iran started a malaria elimination program with WHO technical support. This program's goal was to make Iran a malaria-free country by the end of 2025 [4, 6]. Iran has reduced annual malaria cases due to local transmission in the endemic area to less than 100 cases, with zero deaths in 2017 [7]. Imported malaria can hinder the progress of the malaria elimination program as a problem. According to WHO, imported malaria defines as a *Plasmodium* infection that is acquired in a malaria-endemic area but diagnosed in a non-endemic area after developing clinical symptoms [8]. On the other hand, imported malaria remains a significant clinical problem due to the misdiagnosis and rapid potential progression to a severe and life-threatening disease, especially in children and non-immune patients [9].

Imported malaria to Iran mostly comes from illegal immigrants from neighboring eastern countries, including Pakistan and Afghanistan, which have slow progress programs for malaria control.

In the present study, we describe an imported malaria case in a 14-month-old Afghan boy hospitalized in Shahid Beheshti, Kashan, central Iran.

**CASE PRESENTATION**

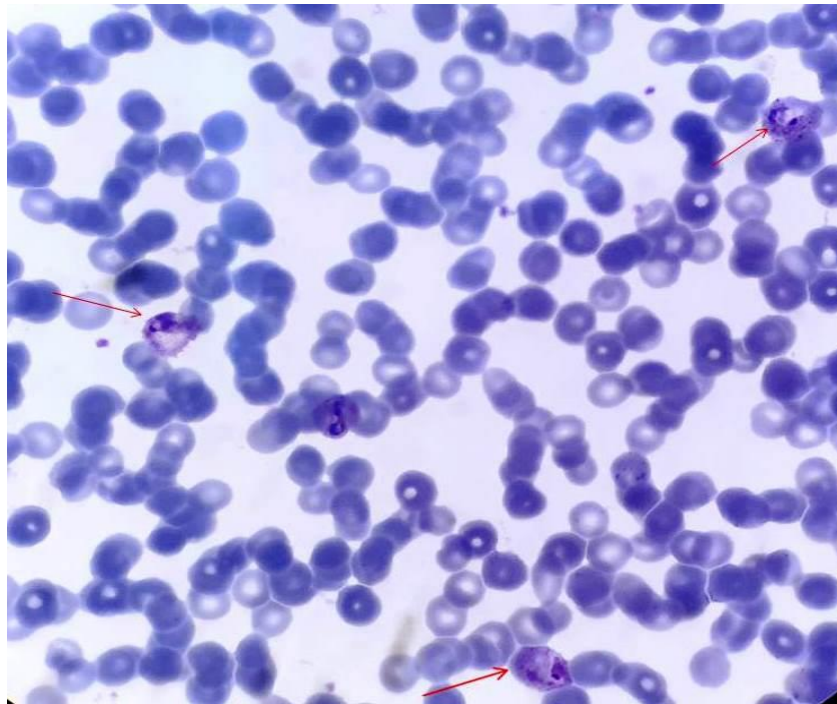
A 14-month-old Afghani boy who had experienced a prolonged fever for two weeks, vomiting, and diarrhea was referred and hospitalized in the Shahid Beheshti Hospital, Kashan, central Iran, in December 2021. He was born and a resident of Afghanistan until the end of his first birthday. He and his parents traveled and immigrated to Kashan, Iran, three weeks before hospitalization. He received symptomatic treatment because of fever and diarrhea before admission to the hospital. The patient weighed 9.7 kg and, in clinical examination, showed febrile (39 °C), with a blood pressure of 110/60 mm Hg.

Oxygen saturation in the air was 95%. Real-time PCR for COVID-19 and serological tests for HIV and brucellosis were negative. His chest X-ray study was regular, and abdominal ultrasound demonstrated the liver in average size, but an enlarged spleen (87 mm) was evident in the sonography diagnostic procedure.

The patient's complete blood count revealed severe anemia with a hemoglobin level of 6 g/dL and platelets of 28000 mm<sup>3</sup>. Other components of the blood test results are reflected in Table1. Additional laboratory data are as included total bilirubin of 1.1mg/dL, direct bilirubin of 0.9 mg/dL, Creatinine (Cr) 0.4 mg/dL. The blood culture for bacteria was negative after five days, and the G6PD test result was normal. The patients received 140 ml of O<sup>+</sup> blood.

**Table 1.** Results of complete cell blood count

CBC count	Result (Unit)	Normal range
RBC	2.85 ×10*6 (UL)	3.9-5.8 ×10*6 (UL)
WBC	4.61 ×10*3 (UL)	4-11 ×10*3 (UL)
PLT	28000 (mm3)	165000-415000 (mm3)
MCV	69.47 (fL)	80-96 (fL)
MCHC	30.3 (g/dL)	32-35.8 (g/dL)
Hb	6 (g/dL)	10.4-13.6 (g/dL)
PT	11 (seconds)	11 (seconds)
ESR	29 (mm/h)	Up to 15 (mm/h)
PTT	30.2 (seconds)	25-35 (seconds)



**Fig. 1.** Red blood cells infected with trophozoites of *P.vivax*. The arrows show infected cells containing Schüffner's dots (X100).

Ultimately, on the seven days of hospitalization, the result of the patient's thin blood smear test after staining

with Giemsa stain showed parasitic trophozoite of *plasmodium* inside the RBC with Schüffner's dots and

large parasitic erythrocytes indicating *P. vivax* infection (Figure 1).

The patient was treated with 50 mg chloroquine orally for three days, followed by primaquine, 2.5 mg once daily for two weeks. Three days after treatment, febrile peaks disappeared, the peripheral blood thin smear became negative for *Plasmodium*, hemoglobin level rose to 12.4, and cell blood count returned to normal. The patient was discharged from the hospital with normal vital signs.

The patient's parents gave their written and signed consent to use the data and results for publication.

## DISCUSSION

Imported malaria is one of the significant challenges hindering the achievement of global malaria control. Indigenous malaria transmission is under control in most countries around the Persian Gulf; however, malaria cases are imported to these countries, especially by the migrant workforces coming to these regions [10].

Malaria was endemic in Iran's three south and southeastern provinces, including Sistan and Baluchistan, Hormozgan, and Kerman. In 2018-2019, Iran reported zero indigenous malaria cases for the first time, but Iranian populations are at risk of malaria, especially residents in south and southeastern Iran [11]. Currently, Iran is in the pre-elimination phase of malaria control, so introducing new malaria cases, i.e., imported cases in areas with unstable situations, may result in disease control failure. In the present case, we reported imported malaria due to *P. vivax* in an Afghan boy that immigrated to Central Iran. It is crucial because Afghanistan and Pakistan are two endemic countries for malaria, and the traffic of immigrants from these neighboring countries seeking a job in Iran is a significant challenge for eliminating malaria [1, 8, 11].

There are some reports of imported malaria from different parts of Iran. For example, Arab Mazar *et al.* (2020) reported a case of malaria due to *P. vivax* in a 48-year-old male patient hospitalized in Tehran with fever attacks, chills, and headaches after arriving from Iraq to Iran [12]. A study on the epidemiology of malaria in the Larestan in the south of Iran (Fars Province), during 2008-2018, showed that among 156 malaria reported cases, only 0.6% of cases had Iranian nationality, 96.2% of cases were Afghanistani, and 3.2% were Pakistani immigrants [13]; the majority of immigrants to Iran have Afghanistan nationality.

A screening test or attention to malaria symptoms in all immigrants before arriving in the country, even in non-endemic regions, is recommended. It has been well established that severe health control programs for refugees and anti-malaria campaigns in border regions can play an essential role in preventing and controlling malaria in the country.

Children account for many imported malaria cases. This group has high-risk factors for developing malaria and severe disease. Malaria in children, especially in the non-endemic area, can be misdiagnosed and associated with long-term morbidity and death [14]. Physicians need to be aware of the usual and unusual signs and symptoms of malaria, especially in children that arrive in non-endemic areas, to reduce misdiagnosis and control the disease.

## CONFLICT OF INTEREST

The authors declare that there are no conflicts of interest associated with this manuscript.

## REFERENCES

1. WHO. World Malaria Report 2021. Geneva: World Health Organization; 2021.
2. Sato S. Plasmodium - a brief introduction to the parasites causing human malaria and their basic biology. *J Physiol Anthropol.* 2021; 40 (1): 1-3.
3. Tangpukdee N, Duangdee C, Wilairatana P, Krudsood S. Malaria diagnosis: a brief review. *Korean J Parasitol.* 2009; 47 (2): 93-102.
4. Vatandoost H, Raeisi A, Saghafipour A, Nikpour F, Nejati J. Malaria situation in Iran: 2002–2017. *Malaria J.* 2019; 18 (1): 200.
5. Nejati J, Moosa-Kazemi SH, Saghafipour A, Soofi K. Knowledge, attitude and practice (KAP) on malaria, from high malaria burden rural communities, southeastern Iran. *J Parasit Dis.* 2018; 42 (1): 62–7.
6. CDC, Ministry of Health and Medical Education. Malaria elimination program in the Islamic Republic of Iran (in the vision 2025). Tehran: Ministry Health and Medical Education; 2008.
7. Schapira A, Zaim M, Raeisi A, Ranjbar M, Kolifarhood G, Nikpour F, et al. History of the successful struggle against malaria in the Islamic Republic of Iran. Tehran: Neekpey. 2018 pp: 27-28.
8. Sabatinelli G, Ejov M, Joergensen P. Malaria in the WHO European Region (1971–1999). *Euro Surveil.* 2001; 6 (4): 61-5.
9. Agagliati F, Silvestro E, Denina M, Garazzino S, Mignone F, Zoppo M, et al. Imported malaria in children: A 13 years retrospective study. *Travel Med Infect Dis.* 2022; 46: 102273.
10. Bawazir A, Bansal D, Chehab M, Al-Dahshan A, Bala M, Al-Romaihi H, et al. Malaria chemoprophylaxis for travelers: the knowledge of physicians in the State of Qatar, 2017. *Int J Travel Med Global Health.* 2018; 6 (2): 69-75.
11. Saberi N, Raeisi A, Gorouhi MA, Vatandoost H, Mashayekhi M, Nikpour F, et al. Current situation of malaria and resistance of main vectors to WHO recommended insecticides in an endemic area, southeastern Iran. *J Med Entomol.* 2022; 59 (2): 607–14.
12. Arab-Mazar Z, Roodsari SR, Mirabedyni Z, Haghighi L, Rahimi M. Imported Malaria in an Iraqi Immigrant to Iran: Relevance for the maintenance of elimination status. *Nov Biomed.* 2020; 8 (2): 98-100.

Taghipour et al.

13. Ebrahimzadeh F, Shookohi G, Sahranavard F, Abolghazi A. The considerable cases of imported malaria in Larestan in the south of Iran during 2008-2018. *Avicenna J Clin Microbiol Inf.* 2020; 7 (2): 56-9.

14. Ladhani S, Aibara RJ, Riordan FA, Shingadia D. Imported malaria in children: a review of clinical studies. *Lancet Infect Dis.* 2007; 7 (5): 349-57.

**Cite this article:**

---

Taghipour T, Erami M, Fakhrei M, Hooshyar H. Imported Malaria in an Immigrant Toddler Boy in Kashan, a Non-Malaria Endemic Area, Central Iran. *J Med Microbiol Infect Dis*, 2022; 10 (3): 149-152. DOI: 10.52547/JoMMID.10.3.149