Journal of Medical Microbiology and Infectious Diseases

JoMMID
ISSN: 2345-5349
eISSN: 2345-5330

Pathological Effects of COVID-19 on Body Organs

Sabereh Ahmadzadeh[1], Mehrnoosh Sedighi[2], Amin Torkashvand[3], Pejman Hashemzadeh[4], Fateme Shafiei[5], Mohammad Torkashvand[6], Atefeh Hasan-Zadeh[6*]

[1]School of Pharmacy, Shahid Sadoughi University of Medical science, Yazd, Iran; [2]Lorestan University of Medical Sciences, Khorramabad, Iran; [3]Malayer Faculty of Nursery, Hamedan University of Medical Sciences and Health Services, Malayer, Hamedan, Iran; [4]Department of Medical Biotechnology, Faculty of Medicine, Lorestan University of Medical Sciences, Khorramabad, Iran; [5]Cardiovascular Research center, Shahid Rahimi Hospital, Lorestan University of Medical Sciences, Khoramabad, Iran; [6]Fouman Faculty of Engineering, College of Engineering, University of Tehran, Fouman, Iran

ARTICLE INFO

Review Article

Keywords: COVID-19, Pathogenesis, SARS-COV-2 Infection, Viral infections

Received: 13 Jun. 2022
Received in revised form: 20 Nov. 2022
Accepted: 18 Apr. 2023
DOI: 10.52547/JoMMID.11.1.1

***Correspondence**
Email: hasanzadeh.a@ut.ac.ir
Tel: +981334915118
Fax: +981334916121

© The Author(s)
CC BY NC ND

ABSTRACT

The SARS-COV-2 virus is the cause of the 2020 pandemic that has infected and killed millions worldwide. While the upper respiratory tract cells are the primary targets of COVID-19, the virus can infiltrate other tissues and organs, leading to potentially serious complications. The new coronavirus primarily affects angiotensin II receptor and cytokine pathways, which can result in acute pulmonary inflammation, pulmonary edema, acute respiratory distress syndrome, vascular endothelial dysfunction, pulmonary embolism in the lungs, and cardiomyopathy, arrhythmia, heart failure, and intravenous thrombosis in the heart. COVID-19 infection can be associated with gastrointestinal symptoms such as diarrhea, vomiting, and abdominal pain. Also, reports of mild and transient liver damage, polyneuropathy, encephalitis, stroke, acute renal failure, hypocortisolism, and damage to the hypothalamus and pituitary system are available. COVID-19 can also be associated with skin symptoms such as rash, urticaria, maculopapular lesions, and vascular lesions such as chill blain, petechiae purpura, and scalpopathy. This narrative review evaluates the pathogenesis of novel coronavirus on body organs based on relevant published papers and reference books.

INTRODUCTION

On January 30, 2020, the World Health Organization (WHO) officially named the pneumonia infection caused by the SARS-COV-2 virus COVID-19. It is a giant single-stranded RNA virus belonging to the *Coronaviridae* family and the *Nidovirales* order. The phylogenetic analysis of the COVID-19 genome from Wuhan, China, revealed it belongs to the β-CoV-2 receptor [1].

The virus has the typical protein appendages on membranes and comprises proteins, nucleoproteins, and membrane proteins such as polymerases, proteases, helixes, and other auxiliary proteins [2].

The 96.2% similarity sequence of this virus and those in the bat *Rhinolophus affinis* in the Wuhan city of China indicated bats as the probable natural host. Also, the genetic differences hinted at another intermediate host, e.g., the small mammalian pangolin, harboring a strain with 99% similarity to the COVID-19 genome. Once COVID-19 S protein binds to Angiotensin-converting enzyme 2 (ACE-2) receptors, it can enter the target cells in the upper respiratory tract, potentially leading to the clinical symptoms of acute respiratory distress syndrome in 4% of cases. The significant affinity between the coronavirus and these receptors indicates that populations with higher ACE-2 expression are more at risk of infection with this virus [3].

Although the overall mortality rate of this virus is 3.4%, it is significantly higher in elderly individuals and those with underlying health conditions [4]. The most common infection routes in humans include direct transmission by respiratory droplets and saliva when coughing and sneezing, person-to-person transmission, and contact with the oral, nasal, and eye mucous membranes. Indirect transmission is also possible through contact with contaminated surfaces. The virus may remain for several days and act as a secondary source [5].

[Downloaded from jommid.pasteur.ac.ir on 2026-01-29]

[DOI: 10.52547/JoMMID.11.1.1]

The incubation period is 2-14 days after the virus enters the body [6-7]. The prevalence of the virus is slightly higher in men than in women. After the incubation period, most infected people have clinical symptoms of mild to moderate respiratory illness, such as fever, dry cough, fatigue, muscle aches, and shortness of breath. Most of them can be cared for at home without particular treatment protocols. Older people with underlying diseases, such as cardiovascular disease, high blood pressure, diabetes, obesity, chronic respiratory disease, or cancer, are typically more susceptible to a severe form of the virus. Clinical symptoms in severe patients include shortness of breath, chronic pain or pressure in the chest, and bruising of the lips or face [7-9]. Complications such as pneumonia, respiratory hypoxia, shock, multiple organ failure, thromboembolism, gastrointestinal bleeding, polyneuropathy, and myopathy lead to extended hospitalization and potentially fatal outcomes.

Laboratory results in these patients show the Erythrocyte Sedimentation Rate (ESR), high D-dimer level, and lymphocyte reduction (lymphocytopenia) in the peripheral blood sample [7-10].

The infecting mechanism of coronavirus is primarily associated with angiotensin II receptor and cytokine pathways, which can cause acute pulmonary inflammation, pulmonary edema, acute respiratory distress syndrome, vascular endothelial dysfunction, and pulmonary embolism in the lung and cardiomyopathy, arrhythmia, heart failure, intravenous thrombosis in the heart. These are the leading causes of the high death rates in these patients. This review aims to evaluate the pathogenesis of novel coronavirus on body organs.

METHOD

This paper discusses the pathogenesis of the new coronavirus on body organs, the impact on some vital organs, and the molecular mechanisms involved in this disease based on 184 articles available in various online databases such as Web of Science, Scopus, Pubmed, and reference books. However, different COVID-19 strains affect the body's organs, as summarized in Table 1.

Table 1. COVID-19 strains and pathogenesis

Variants Being Monitored (VBM)		
WHO Label	**Pango Lineage**	**References for Pathological effects**
Alpha	B.1.1.7 and Q lineages	[11-13]
Beta	B.1.351 and descendent lineages	[12-16]
Gamma	P. 1 and descendent lineages	[12-14, 17, 18]
Delta	B.1.617.2 and AY lineages	[12-14, 18]
Epsilon	B.1.427 B.1.429	[13, 19, 20]
Eta	B.1.525	[13, 21, 22]
Iota	B.1.526	[13, 23, 24]
Kappa	B.1.617.1	[13, 25, 26]
N/A	B.1.617.3	[13, 27, 28]
Zeta	P.2	[13, 28, 29]
Mu	B.1.621, B.1.621.1	[13, 30, 31]
The variant of Interest (VOI)		
Currently, no SARS-CoV-2 variants are designated as VOI.		
The variant of Concern (VOC)		
Omicron	B.1.1.529 BA.1 BA.1.1 BA.2 BA.3 BA.4 BA.5	[12-14, 18, 32, 33]

Pulmonary effects

Inflammation related to a viral infection can lead to cellular transformation by activating several carcinogenic pathways. COVID-19 infection and cancer in various organs are the leading causes of concern. SARS-CoV-2 infection can activate some carcinogenic pathways that persist within cells for extended periods, causing inflammation and cellular transformation. These pathways may remain active even after virus clearance [34-35].

These issues can have severe effects on patients with SARS-CoV-2. For example, MERS can activate various carcinogen factors such as MEKK, MAPK, ATF2, C-Fos, p90RSK, Raf-1, and JNK by mediating AP-1 while suppressing the autophagy regulation of Bcl-2 family proteins [36, 37].

Infected individuals may experience alveolar dysfunction, regulated expression of the ACE2 receptor, immunosuppressive cytokines, and cytotoxic immune cell dysfunction [38, 39]. A CT lung screening may indicate the presence of Ground Glass Opacity (GGO) within the patient’s lungs. GGO can cause blurred vision, absence of bronchi, vascular area, slight alveoli collapse, and thickening of the interstitial space, commonly more reported in high-risk populations [40, 41].

[Downloaded from jommid.pasteur.ac.ir on 2026-01-29]

[DOI: 10.52547/JoMMID.11.1.1]

Therefore, the central organ targeted by SARS-COV-2 infection, the lungs, is easily impaired. In the later stages of COVID-19, shortness of breath, pneumonia symptoms, and hypoxia are common clinical manifestations that can be lethal to patients. It activates metallopeptidase domain 17, causing acute pulmonary inflammation and cytokine and leukocyte infiltration into the alveolar space, which can lead to pulmonary edema (Fig. 1) [42-43].

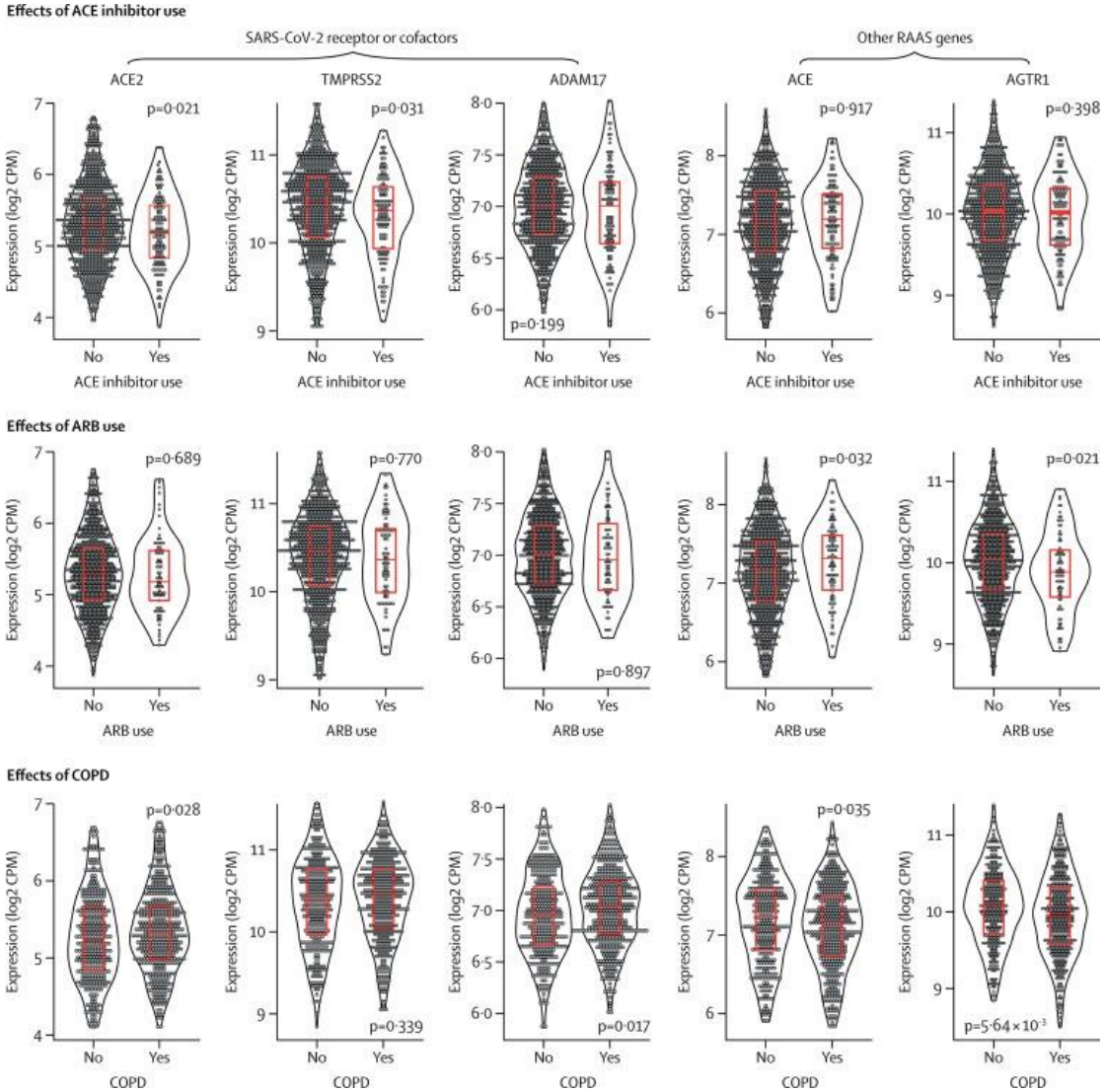

Fig. 1. Expression of SARS-CoV-2 receptor or cofactors and RAAS-related genes in human lung tissue gene expression and phenotype data from 1051 participants in the Lung eQTL Study. Violin plots illustrate the distribution of gene expression levels in log2 CPM (outliers have been removed). Superimposed box plots display the median (IQR). *P*-values were derived from robust linear models adjusted for current smoking status. ARB=angiotensin II receptor blocker. COPD=chronic obstructive pulmonary disease. CPM=counts per million. eQTL=expression quantitative trait loci. RAAS=renin–angiotensin–aldosterone system. SARS-CoV-2=severe acute respiratory syndrome coronavirus 2, [43].

In response to viral infection, excessive systemic inflammation against COVID-19 disease leads to cytokine storms and respiratory problems, with the highest mortality [44]. Pulmonary complications such as acute respiratory distress syndrome (ARDS), vascular endothelialization, sepsis, pulmonary edema, and pulmonary embolism occur following a COVID-19 infection [44-46]. A multi-center study conducted across 235 hospitals in 24 countries, which included 1128 patients and 294 confirmed COVID-19 cases, indicated that up to 51.2% of subjects experienced pulmonary complications after surgery. This study attributed most deaths to pulmonary embolisms [46]. The results also showed increased thrombosis and microangiopathy in COVID-19 compared with influenza. Moreover, acute respiratory failure and cytokine storms, which reduce oxygen delivery, could potentially result in acute myocardial damage in these patients [47].

[Downloaded from jommid.pasteur.ac.ir on 2026-01-29]

[DOI: 10.52547/JoMMID.11.1.1]

Poor baseline health is associated with an increased risk of severe respiratory complications from the coronavirus. Although rare, respiratory muscle dysfunction is more prevalent in patients with poor baseline health, particularly those with obesity [48]. In a cross-sectional study conducted by Panroni et al. (2021), recovering patients discharged from the COVID-19 ward were evaluated for improved skeletal muscle strength and physical performance (using 1-min sit-to-stand and short physical performance battery tests), as well as dyspnea, fatigue, and single-breath counting. The high prevalence of impaired skeletal muscle strength and physical function in hospitalized patients with improved COVID-19 pneumonia without prior motor disability indicated the need for ongoing physical function follow-up and rehabilitation programs [49].

Cardiac effects

Patients with baseline cardiovascular disease have a higher mortality rate (10.5%) than those with chronic respiratory disease (6.3%). Patients with cardiovascular disease (CVD) may have more severe COVID-19 disease with higher mortality. It is mainly because of a more elevated angiotensin-converting enzyme (ACE) in the cardiovascular system, which acts as a gateway for the virus to enter the lungs and heart [50]. Respiratory and acute cardiac diseases are significant clinical symptoms that can be observed in patients during the later stages of SARS-COV-2 infection [51].

Patients with coronary artery disease or heart failure are at a higher risk of developing heart damage. When such patients become infected with SARS-COV-2, they are at serious risk for myocardial infarction or heart failure. This unexpected deterioration can increase the need for hospitalization, resulting in a higher mortality rate [52]. Cardiac complications associated with COVID-19 include myocardial dysfunction, cardiomyopathy, arrhythmias, and heart failure (Fig. 2) [53-55].

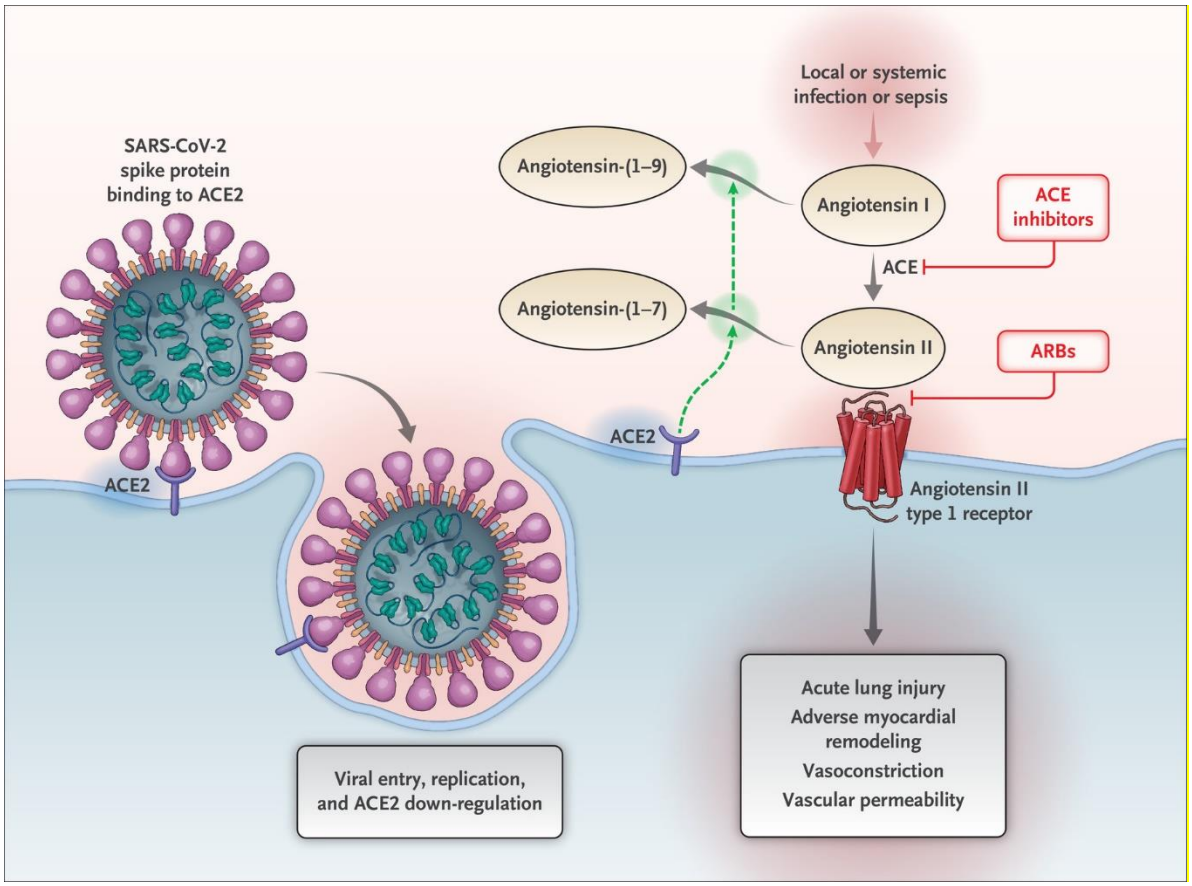

Fig. 2. Interaction between SARS-CoV-2 and the renin–angiotensin–aldosterone system [55].

Respiratory arrest, as well as cardiovascular complications, respiratory and cardiac arrest, high blood pressure, diabetes, ischemic heart disease, and heart failure, are considered to be the most significant risk factors for mortality [53]. The renin-angiotensin-aldosterone system (RAAS) is an enzyme cascade that plays a crucial role in maintaining circulatory homeostasis, fluid balance, and systemic vascular resistance, all of which contribute to regulating cardiovascular systems and controlling blood pressure

[Downloaded from jommid.pasteur.ac.ir on 2026-01-29]

[DOI: 10.52547/JoMMID.11.1.1]

[56]. Angiotensin-converting enzyme 1 (ACE1) is responsible for converting angiotensin I (Ang-I) to angiotensin II (Ang-II), which then activates the angiotensin receptor type 1 (AT1R) and can lead to vasoconstriction, inflammation, fibrosis, and proliferation [57].

Then, ANGII is inactivated by converting to angiotensin-1-7 through ACE2. Angiotensin binds to the MAS receptor (MAS-R) and has anti-inflammatory and vasodilator effects. ACE2 can also convert Ang-I to angiotensin1-7, albeit with lower affinity, which may help prevent the progression of hypertension, cardiac hypertrophy, and heart failure [58]. An increase in the ACE2/ACE1 ratio can help protect against endothelial functions and vasoconstriction, and activation of extracellular ACE2 can weaken thrombus formation and reduce platelet aggregation [59-60].

However, SARS-COV-2 enters the cardiovascular cell/tissue by binding to ACE2 receptors. An elevated level of ACE2, as a biomarker of cardiovascular disease, including in patients with heart failure, may indicate that these patients are more susceptible to COVID-19 infection [61]. Measurements of plasma angiotensin peptides and plasma ACE2 levels can indirectly assess the treatment and status of the renin–angiotensin–aldosterone system in COVID-19 patients [62].

The mechanisms of heart damage are still unclear. Undoubtedly, the difference between increased metabolic demand and poor cardiovascular storage may be one of the potential mechanisms that can affect heart function and the possible direct effects of pneumonia. Another mechanism can be overexpression of the angiotensin-converting enzyme 2 (ACE2) in heart tissue [63]. In patients with pre-existing cardiovascular disease, the symptoms of COVID-19 appear to be more severe. Also, the expression of ACE2 increases in these patients. So, by better understanding COVID-19 damage to the heart and its pathways, the treatment provided to these patients can be accurate and effective, leading to reduced mortality. Administration of ACE inhibitors or angiotensin II receptor blockers may be justified and beneficial in cases where severe metabolic demand and cardiac dysfunction are observed, especially in patients with hypertension, diabetes, and heart disease [64].

Evidence suggests that these drugs can regulate ACE2, the receptor used by SARS-COV-2 to attack host cells. However, given the critical role of ACE2 in SARS-CoV-2 infection, it is essential to exercise caution when considering the potential effects of antihypertensive drugs that involve angiotensin receptor blockers or ACE inhibitors in hospitalized COVID-19 patients, mainly as these drugs may increase the level of ACE2 [65]. A comprehensive case report of 138 patients showed that 16.7% had arrhythmia and 7.2% had acute heart damage [66].

Other mechanisms for heart damage include overexpression of cytokines activated by type 1 and 2 T-helper cells [50], hypoxemia, and respiratory dysfunction stimulated by SARS-COV-2 [67]. Inflammatory markers, such as high-sensitivity C-reactive protein (hs-CRP) and cardiovascular risk-related cytokine levels, are associated with adverse outcomes and can serve as biomarkers and risk factors [68]. Currently, no targeted treatment for COVID-19 is available, and management mainly involves controlling the spread of the disease by implementing travel restrictions, quarantining infected patients, and providing supportive care.

Myocarditis

Myocarditis is characterized by heart muscle inflammation, often a dual viral infection. This condition can cause inflammation that disrupts the heart's electrical system, leading to arrhythmias and cardiac arrest [69]. To diagnose this condition, physicians may use standard methods such as the electrocardiogram (ECG), magnetic resonance imaging (MRI), or measure the amount of troponin I (cTnI) in the heart. COVID-19 patients with severe disease may experience systemic hyperinflammatory syndrome. The data suggests that an adverse inflammatory response or cytokine storm may occur in response to COVID-19 treatment [70], highlighting the critical role of ACE2 signaling in COVID-19 disease. Several reports have identified the development of myocarditis in patients with COVID-19 infection [71-74].

Myocarditis patients typically exhibit specific characteristics such as left ventricular hypertrophy (LVH), high left ventricular volume, and a reduced ejection fraction (35%), as determined by echocardiography. Furthermore, the left ventricle typically retains normal wall movement despite elevated plasma troponin levels (9.0 ng/ml). These reports indicate that patients with COVID-19 infection are prone to myocarditis, especially if they have underlying conditions like hypertension or other cardiovascular diseases [75, 76]. Physicians are mindful of these risk factors and watch for myocarditis in COVID-19 patients [75, 76].

Recent clinical and epidemiological evidence suggests that metabolic disorders, hypoxia, and SARS-CoV-2-induced myocardial infarction contribute significantly to the pathophysiology of myocardial injury and the prevalence of arrhythmic complications [77]. A study conducted in Wuhan, China, on 138 COVID-19 patients revealed that cardiac arrhythmias were a significant complication in 23 ICU patients (16.7%) [74].

Cardiac arrhythmias are notably more prevalent in ICU patients compared to non-ICU patients. COVID-19-induced myocarditis coupled with cardiogenic shock can trigger atrial and ventricular arrhythmias, exacerbating the severity of COVID-19 complications [78, 79]. Given the risk that COVID-19 poses to cardiac health, healthcare professionals must take additional precautions and

[Downloaded from jommid.pasteur.ac.ir on 2026-01-29]

[DOI: 10.52547/JoMMID.11.1.1]

implement exceptional management practices. Current clinical data suggests that possible myocardial injury is a considerable challenge for hospitalized COVID-19 patients and has been linked to a high mortality rate. Therefore, multidisciplinary evaluation, including blood pressure control in patients with hypertension, and cardiovascular assessment, is essential for managing COVID-19 infection [80].

While we do not yet fully understand the molecular mechanism of heart damage and cardiac arrhythmia caused by the SARS-CoV-2 virus, overexpression of ACE-2 receptors in the heart has been shown to play a critical role in the accumulation of the virus in cardiac tissue, leading to increased inflammation and heart damage [81]. Another study using potent human stem cell-derived cardiomyocytes (hiPSC-CMs) found that SARS-COV-2 can directly infect hiPSC-CMs, leading to apoptosis and cardiac arrest after 72 hours of infection [82]. COVID-19 patients with cardiovascular complications typically exhibit slight increases in TnI, NT-proBNP, interleukin-6 (IL-6), and other cytokines. Also, the roles of chemokine 10 (CXCL10), chemokine 2 ligand (CCL2), granulocyte-macrophage colony-stimulating factor (GM-CSF), and tumor necrosis factor-α (TNF-α), which are abundant in the bloodstream of COVID-19 patients, remain unclear [54, 83, 84].

Severe inflammation or cytokine storm due to immune dysregulation may cause heart damage [85]. Epidemiological studies involving other viral RNAs show that once the virus enters the cytoplasm of cardiomyocytes, it transcribes viral RNA and translates it into viral structural proteins to produce a complete infectious virus that infects the cell [86]. Eventually, the virus infecting heart tissue can lyse its cells, triggering the innate immune response by inducing proinflammatory cytokines. This can ultimately stabilize inflammatory coronary artery plaques and disrupt left ventricular function [87].

This systemic inflammation is the critical mechanism of heart damage in COVID-19 patients with severe cardiovascular complications [87]. Studies have shown that Notch signaling plays a crucial role in maintaining cardiovascular homeostasis, including the progression of atherosclerosis and ventricular regeneration after myocardial infarction. Therefore, targeting Notch activation with secretase inhibitors (GSI) may influence treatment strategies for preventing virus entry into heart cells by reducing ADAM17. ADAM10/ADAM17 expresses the Notch on the cell membrane, leading to its final cleavage by γ-secretase and the creation of an active Notch intracellular domain that regulates the transcription of target genes in the nucleus. Furthermore, Notch activation modulates the activity of both innate and adaptive immune reactions by macrophage polarization [88].

Effects on blood pressure

Clinical data suggest that hypertension is a crucial factor in COVID-19 mortality, with a significantly higher risk of COVID-19 in hypertensive individuals. A comparative analysis of severe COVID-19 complications versus mild to moderate disease concluded that CVD was significantly associated with increased disease severity and complications in patients [89]. In addition, another study of 191 patients from two hospitals in Wuhan, China, reported that 48% of patients had baseline factors: 30% high blood pressure, 19% diabetes, and 8% coronary heart disease [54].

Another study involving 1591 COVID-19 patients (between February 20 to March 18, 2020) with a mean age of 63 years from Lombardy, Italy, showed that 68% of patients % had at least one underlying disease such as hypertension (49%), hypercholesterolemia (18%), or diabetes (17%) [72]. Elderly patients, particularly older men with hypertension, may be at a higher risk of infection and experience a higher mortality rate than younger people. Patients with high blood pressure are typically treated with ACE inhibitors (ACEi) and angiotensin II receptor blockers (ARB). However, these treatments can significantly increase ACE2 expression by activating negative feedback against low Ang-I in the system [90].

Given that ACE2 is a preferred receptor for SARS-COV-2, there is a theoretical concern that patients with hypertension treated with ACEi/ARB may be at an increased risk for severe COVID-19. However, no clinical data support this hypothesis, and no evidence suggests using ACEi or ARB (type-I receptor blockers) is a risk factor in COVID-19 patients [58]. Several studies have demonstrated the potential therapeutic effect of ACEi or ARB in preventing COVID-19 infection [91, 92]. Furthermore, Independent studies conducted on hypertensive patients found no association between the use of ACEi or ARB and an increased risk of mortality in COVID-19-positive cases [93, 94].

Therefore, further research is essential to clarify the contradictory hypotheses regarding using ACEi or ARB to control blood pressure in patients with hypertension during viral infections. SARS-COV-2 enters cells via ACE2 receptors and reduces ACE2 regulation by intracellular degradation after overbinding to the receptor. This degradation process can minimize the degradation of Ang-II and activate AT1R, inducing a myocardial hyperinflammatory reaction that decreases blood pressure [58].

Effects on blood vessels

Endothelial cell damage is a critical factor in the pathogenesis of multiple organ failure in COVID-19. The endothelium, one of the largest organs in the human body [73], expresses ACE2 receptors that allow viral entry and contribute to major clinical diseases such as hypertension [72-76], kidney disease [77], cerebrovascular disease, and neurological disorders [78, 79].

[Downloaded from jommid.pasteur.ac.ir on 2026-01-29]

[DOI: 10.52547/JoMMID.11.1.1]

Endothelial cells play a crucial role in protecting the cardiovascular system by releasing essential proteins that regulate blood clotting and the immune response. Endothelial damage can result in excessive cardiovascular damage and causes temporary heart attacks in COVID-19 patients. Endothelial cell damage may cause inflammation of blood vessels, leading to plaque rupture and heart attack. In COVID-19 patients, the destructive response of the immune system and cytokine storm can cause inflammatory heart failure and worsen the condition of the heart. Also, fibrosis occurs in tissue by free radicals following endothelial dysfunction [95].

In COVID-19 patients with underlying diseases, the endothelial dysfunction's response to infection can activate the coagulation pathways [84-96]. Krill *et al.* (2020) and Bompard *et al*. (2020) reported the possibility of deep vein thrombosis and acute pulmonary embolism in COVID-19 patients [97, 98]. These data support the association between baseline endothelial disorder and increased risk of venous thromboembolism, systemic vasculitis, endothelial cell apoptosis, and inflammation in various organs in SARS-COV-2 infected patients [45, 99-101].

The virus is known to bind to the ACE2 receptors expressed on endothelial cells, causing damage to host tissue. This can lead to infection and inflammation in vascular endothelial cells [45, 102-103]. Patients with arterial infection caused by coronavirus often exhibit vascular inflammation, endothelial dysfunction, and excessive coagulation. Some studies have reported abnormalities in the coagulation system in patients with novel coronavirus pneumonia (NCP), which can rapidly induce thrombus formation [45, 102].

Gastrointestinal symptoms

Although patients with COVID-19 usually exhibit fever and respiratory symptoms, some may experience gastrointestinal symptoms such as diarrhea, vomiting, and abdominal pain. Studies have identified the presence of SARS-COV-2-RNA in anal swabs and fecal samples of COVID-19 patients, even after clearance of the virus in the upper respiratory tract. In addition, the ACE2 receptor enzyme is expressed in gastrointestinal epithelial cells, indicating that SARS-COV-2 can actively infect and proliferate in the gastrointestinal tract. This is important for disease management, transmission, and infection control [104].

Liver effects

Liver damage caused by SARS-COV-2 is typically mild, transient, and reversible, with hepatocellular injury being more common than cholestatic injury. The exact mechanism of SARS-COV-2 liver damage remains unclear, but drug-induced liver injury and secondary liver injury may be caused by systemic inflammatory response syndrome or hypoxia in COVID-19. However, further investigation is needed to understand the underlying mechanism fully. Healthcare professionals should carefully manage existing liver diseases and regularly monitor the liver function of patients with COVID-19. Liver-protective anti-inflammatory drugs may be essential in managing liver damage associated with COVID-19 [105].

The Central Nervous System (CNS) effects

Neurotropic viruses can enter and invade nerve tissue, causing significant damage to the structure and function of the nervous system. They can also cause infections in the CNS's immune system components, such as macrophages, microglia, or astrocytes [106]. Viral infections in the CNS can result in injuries such as severe encephalitis, toxic encephalopathy induced by severe systemic viral infections, and severe acute myelination lesions [107].

SARS-COV-2 is very similar in genomic sequence and clinical symptoms to SARS-CoV and MERS-CoV. Previous clinical and preclinical evidence has reported that the brain is the primary target of coronaviruses [108]. SARS-CoV and MERS-CoV were also identified in the cerebrospinal fluid (CSF) of patients infected with these viruses in the early 2000s [109]. In addition, SARS-CoV virus antigen was significantly detected in several brain regions of infected patients, including olfactory bulbs, piriform, cortical layers under the limbic, basal ganglia (abdominal pallidum and areas before lateral cavity), and midbrain (dorsal raphe) [110].

SARS-CoV can also induce neurological diseases such as polyneuropathy, encephalitis, and ischemic stroke [111]. Autopsies have shown that most SARS-CoV cases exhibit cerebral edema and dilation of the meningeal arteries. In addition, infiltration of monocytes and lymphocytes into the vessel wall, ischemic changes in nerve cells, nerve fibers demyelination, SARS-CoV-1 particles, and genome sequences in the brains of SARS-CoV-1 infected patients have been reported [112, 113].

Approximately 1.5% of patients with MERS-CoV infection have shown neurological symptoms, including impaired consciousness, paralysis, ischemic stroke, Guillain-Barré syndrome, and other intoxications or infectious neuropathy [114]. Given the genetic similarities between SARS-CoV-2 and other viruses within the beta-coronavirus family, observing neurological symptoms and complications in COVID-19 patients is unsurprising. Various studies have reported that over one-third of COVID-19 patients exhibit different neurological symptoms such as 1) central nervous system symptoms including; headache, lethargy, unsteady gait, restlessness, cerebral hemorrhage, meningitis and brain stroke, ataxia, epilepsy, 2) peripheral nervous system symptoms such as taste disturbance, olfactory dysfunction, and visual impairment in a large number of COVID-19 patients report, suddenly. Therefore, patients with COVID-19 may have a higher likelihood of

[Downloaded from jommid.pasteur.ac.ir on 2026-01-29]

[DOI: 10.52547/JoMMID.11.1.1]

experiencing anosmia, dysgeusia, and skeletal muscle damage [115-117].

A study involving 241 COVID-19 patients found that over one-third exhibited neurological manifestations, with severity varying depending on the progression of the disease. For example, patients with more severe infections showed acute cerebrovascular disease, impaired consciousness, and skeletal muscle injury [117]. A different study highlighted acute necrotizing encephalopathy (ANE) in a COVID-19 patient through magnetic resonance imaging (MRI). The brain MRI revealed a subdural hematoma and increased bilateral intra-thalamic lesions in the internal temporal lobes and subinsular area (Fig. 3) [118].

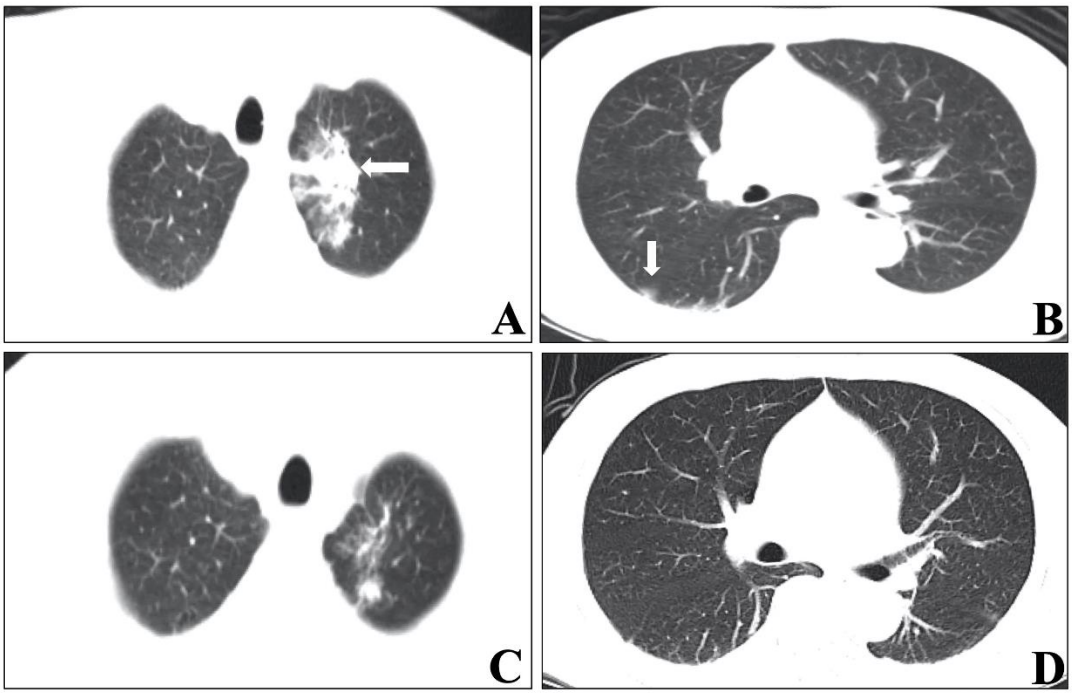

Fig. 3. Chest CT imaging of the patient with COVID-19. On the chest CT scan, a patchy, high-density blurred shadow was observed in the upper lobe of the left lung (Fig. 1A), and a patchy ground glass shadow was detected in the anterior segment of the upper lobe of the right lung (Figure 1B). Following treatment, a subsequent chest CT scan showed that the previous lesions had almost been absorbed [118].

SARS-COV-2 entry and action on the CNS

Although several ways are suggested for SARS CoV-2 to enter the nervous system, the exact means by which it affects the nervous system remain unclear. However, viruses' genetic material and proteins found in cerebrospinal fluid (CSF) and CNS tissue samples indicate that the virus directly attacks the central nervous system. The virus can also enter the brain via the circulatory system. Infection of the CNS by the virus can occur through viral transcytosis in endothelial cells of the blood-brain barrier (BBB) or by infecting the epithelial cells of the blood-brain-cerebrospinal fluid (BCSFB) in the choroidal network (CP) of the ventricles [119, 120].

Viruses can migrate by infecting the sensory or motor nerve endings, whereby they achieve retrograde or anterograde neurotransmission through motor proteins, dynein, and kinesins [121]. One of the neural pathways is transmission through neurons and olfactory bulbs in the nasal cavity [122]. Thus, after CoV enters the nasal cavity and infects its cells, it can reach the brain and cerebrospinal fluid through the olfactory nerve and bulb within seven days, causing inflammation and a demyelinating reaction. Removal of the olfactory bulb in mice limits CoV attack in the CNS [123].

COVID-19-induced nerve injury can also occur via hypoxia and increased anaerobic metabolism in the mitochondria of brain cells. Acid accumulation can cause dilation of cerebral arteries, swelling of brain cells, interstitial inflammation, obstruction of cerebral blood flow, and even ischemia and congestion headaches. Prolonged hypoxia can worsen cerebral edema and circulatory disorders, leading to increased blood pressure in the brain. This can gradually cause brain dysfunction, drowsiness, sciatica, and coma [124].

Severe hypoxia is common among COVID-19 patients [125] and can cause irreversible neurological damage to the CNS. The immune system may also damage the nervous system in response to viral infection [126]. The pathology of severe viral infections is often closely related to developing a systemic inflammatory response syndrome (SIRS). SIRS can start abnormally in severe COV-induced pneumonia. However, taking early anti-

[Downloaded from jommid.pasteur.ac.ir on 2026-01-29]

[DOI: 10.52547/JoMMID.11.1.1]

inflammatory action can help prevent damage to the immune system and reduce the risk of damage to the nervous system [127].

In addition, SARS and COVID-19 have resulted in numerous deaths, many of which are caused by multiple organ failure (MOF) resulting from SIRS following viral infection or SIRS-like immunodeficiency disorders [128, 129]. A neurotropic virus may stimulate glial cells and induce a proinflammatory state [130]. This becomes particularly relevant when considering Interleukin-6 (IL-6) is a proinflammatory cytokine directly associated with COVID-19 symptoms [131]. In addition, *in vitro* studies have reported that cultured glial primary cells can secrete large amounts of inflammatory agents such as IL-6, IL-12, IL-15, and TNF-α following CoV infection [123]. These can also cause chronic inflammation and may even lead to brain damage. ACE2 has been identified as a cardiovascular protective factor in several organs, including the nervous system and skeletal muscle [132].

SARS-COV-2 may invade nerve tissue via ACE2 or TMPRSS2 receptors [119]. Interestingly, the ACE2 receptors are also expressed on the spinal cord membrane, and the virus may invade the spinal cord by binding to ACE2 receptors on the surface of neurons. Thus, ACE2 is an essential target for various CoV and influenza viruses [50]. The binding of the COVID-19 virus to ACE2 receptors may cause an abnormal increase in blood pressure and an increased risk of cerebral hemorrhage [133]. Serum samples from COVID-19 patients indicate a change in blood coagulation and long-term prothrombin [134].

As a precautionary measure, hypertensive patients with SARS-COV-2 are advised to avoid using ACE inhibitors or angiotensin II receptor blockers (ARBs) as antihypertensive drugs and blockers. Instead, other classes of antihypertensive medications - such as calcium channel blockers or diuretics - should be considered [135]. SARS-COV-2 may also penetrate the cribriform plate near the olfactory bulb (OB) and olfactory epithelium (OE), allowing it to potentially inhibit olfactory receptor neurons (ORNs) or non-neuronal cells situated in the OE. This could occur through the use of ACE2 or TMPRSS2 receptors by the virus [110].

ACE2 and TMPRSS2 receptors have a high-level expression in the olfactory mucosa of both humans and mice, and their expression is increased with age in the mouse model [136]. The ACE2 receptor is expressed in neurons and glial cells [122]. Thus, older adults may have a greater risk of SARS-COV-2 accumulation in OE cells [137]. Besides the olfactory nerve, the virus may also use other peripheral nerves- such as the trigeminal nerve or the sensory nerves of the vagus nerve- involved in the respiratory, including those connected to the larynx, trachea, and lungs [138].

Kidney effects

There is a link between coronavirus and acute kidney injury, as the virus can spread through the circulatory system and reach kidney cells, ultimately leading to kidney damage and elevated levels of blood urea nitrogen, serum creatinine, and uric acid [128, 139]. According to the Kaplan-Meier analysis, patients with kidney disease had a significantly higher mortality risk during hospitalization. Notably, the prevalence of renal disease and the development of AKI during hospitalization is high in these patients and can be associated with in-hospital mortality. Given the significant impact of COVID-19 on kidney health, physicians should be mindful of the potential risks to patients with pre-existing kidney disease [128]. Studies suggest that in-hospital mortality rates are 3-9% higher in patients with acute kidney injury than those with chronic kidney disease [139-141].

Mechanism: First, COVID-19 uses the ACE II receptor to enter kidney cells. Infection in kidney cells is very high and comparable to lung cells, with SARS-COV-2 able to infect both distal and proximal cells and renal tubules. The presence of virus RNA in patients' urine samples indicates that the virus can infect kidney cells. As a result, there is an increase in the production of inflammatory factors such as IL2, IL7, IL10, GSCF, IP-10, MCP-1, MIP1A, and TNF-α [142-143], which can ultimately lead to inflammation and edema in kidney cells [139].

Furthermore, SARS-COV-2 has been shown to damage the renal tubules by penetrating the renal parenchyma and increasing levels of inflammatory cells such as CD4+, CD56+, CD68+, and macrophages [144]. This can result in the death of tubular cells, particularly renal tubular cells. Over time, the immune cells may lead to fibrosis, apoptosis, and changes in the arteries of kidney cells [145]. C5b-9 is not present in healthy kidney cells. However, when inflammatory cells and cytokines impact the renal parenchyma, C5b-9 can attack cell membranes, ultimately damaging kidney cells and releasing free radicals. Thus, the indirect presence of cytokines can cause hypoxia, shock, and rhabdomyolysis [145], finally making the kidneys more vulnerable to hypoxia. This lack of adequate blood supply can lead to ischemia and insufficient blood flow. Ischemia can trigger the production of hypoxia-inducible factor 1 (HIF-1), which in turn can lead to the generation of free radicals. HIF-1 can stimulate the expression of genes that promote the formation of fibrous connective tissue and, combined with a cytokine storm and increased levels of free radicals, can lead to nephron damage and cell death [146-147].

Fever-induced dehydration or reduced water intake, especially in older adults, can lead to various consequences, including reduced filtration, acute kidney damage, hypoxia and ischemia in the kidney, shock, and acute necrosis of the renal tubules. Other possible systems, such as sepsis caused by COVID-19, lead to cytokinin syndrome, causing a direct attack of the virus on the kidneys, interstitial cells, tubules, and cytopathic

[Downloaded from jommid.pasteur.ac.ir on 2026-01-29]

[DOI: 10.52547/JoMMID.11.1.1]

effect on kidney cells. In all cases, the virus attacks the kidney cells via the ACE2 receptors [148-149].

Involvement of the kidneys in COVID-19 can occur through direct or indirect mechanisms and is frequently observed in the form of proteinuria and acute kidney injury (AKI). Kidney injury caused by SARS-COV-2 is expected to be multifactorial. SARS-CoV-2 can directly infect kidney cells, including proximal tubular glandular cells, and utilize the angiotensin-converting enzyme (ACE2) pathway to cause acute tubular necrosis, protein leakage in the Bon Bowman's capsule, collapsing glomerulopathy, and mitochondrial dysfunction. Immune responses to infection, such as cytokine storm, macrophage activation syndrome, and lymphopenia, may contribute to the development of AKI. Other potential mechanisms of AKI include organ interactions, endothelial dysfunction, and hypercoagulation.

Skin manifestations

Despite increasing reports of cutaneous manifestations in COVID-19 patients, the exact prevalence and pathophysiological mechanisms of these manifestations remain unclear. Moreover, whether the virus plays a direct or indirect role in their pathogenesis is unclear. The skin patterns associated with COVID-19 are defined as follows:

1. Maculopapular rashes/Morbill form rash, 2- Urticaria, 3. Vesicular lesions, 4. Chill Blaine-like lesions (Covid finger), 5- Livedoid vasculopathy, 6- Livedoid lesion

These manifestations can be divided into various inflammatory types: vesicular, urticarial, maculopapular, vascular lesions, chill-blade, petechiae purpura, and levidoid vasculopathy.

1- Maculopapular/morbilliform lesions: Maculopapular lesions are the most commonly observed skin manifestations associated with COVID-19. They may arise as an adverse effect of therapeutic drugs in adults or as a disease complication in children. According to several studies, the prevalence of maculopapular lesions associated with COVID-19 ranges from 5% to 70%. Reports suggest that these rashes are more commonly observed in middle-aged and older individuals and are more frequently observed on the trunk [150-152].

Although some studies have indicated that maculopapular lesions appear spontaneously and coincide with systemic symptoms, other studies have suggested that there may be a 27 to 28 days delay between the onset of systemic signs and the appearance of skin manifestations. These lesions are more common in patients with severe disease. However, recent studies have shown that these symptoms may not be attributed to the use of drugs (Fig. 4) [150-155].

Fig. 4. A) Chilblain-like lesions in a SARS-CoV-2 positive 12-year-old girl and (B) an 8-year-old boy with a SARS-CoV-2 positive father. SARS-CoV-2, severe acute respiratory syndrome coronavirus-2, [154].

2- Urticaria: Urticaria has been identified as a potential complication of COVID-19 in several studies. These lesions usually present as urticaria or angioedema, characterized by a slightly elevated, erythematous rash with severe itching. There are generally two types of urticaria; acute and chronic [156-157]. Acute urticaria is a self-limiting lesion lasting less than six weeks, while chronic urticaria persists for over six weeks. The frequency of acute urticaria in COVID-19 patients has been reported to range from 7 to 40%, and it appears more common in middle-aged patients. The rash is typically observed on the trunk and sometimes on the limbs.

According to some studies, Urticaria can be observed throughout the body or localized only on the face. Various studies have shown that urticaria often coexists with systemic symptoms. One study reported that patients with urticaria experienced severe pruritus in 92% of cases and attributed the lesions' extent to the disease's severity [158]. Urticaria has been identified in various studies as a potential side effect of several medications, including chloroquine, hydroxychloroquine, ritonavir, and corticosteroids. On the other hand, cytokine storms caused by overactive immune systems are another possible mechanism for developing urticaria [159].

[Downloaded from jommid.pasteur.ac.ir on 2026-01-29]

[DOI: 10.52547/JoMMID.11.1.1]

3- Chillblaine-like lesions (COVID finger): Pernio, also known as chilblains, refers to localized skin inflammation following exposure to cold or humid environments. This condition can cause skin discoloration and swelling of the extremities. In a study on 505 patients, 63% exhibited chilblains-like complications, while other studies have reported this number as ranging from 14.3 to 72% [160]. This condition is more frequently observed in adults and young individuals and tends to affect the fingers and toes.

Chilblains typically appear after the onset of systemic symptoms of COVID-19 and can last for 1 to 2 weeks. They often present as itchy and painful lesions and tend to occur in patients with moderate COVID-19. The exact mechanism behind this complication is still unclear, but according to Bouaziz et al. [158, 160], immune instability, vasculitis, vascular thrombosis, and neoangiogenesis may be involved in its development.

4- Vesicular lesions: Vesicular lesions are sacs filled with clear fluid that form under the epidermis. These lesions are commonly referred to as blisters and typically have a diameter of less than 1 cm and tend to cluster together [161]. The incidence of this lesion in patients with COVID-19 is lower than other skin manifestations (between 3.77 and 15%), and it often occurs in middle-aged patients [151, 152].

The leading site of this complication is the trunk, while in some studies, it has been seen on the extremities. The onset time of this complication varies according to different studies, but it typically occurs after systemic symptoms have developed. One study observed that the vesicular lesions presented along with systemic symptoms [151]. In another study, the potential effect of the COVID-19 virus on cutaneous endothelial vessels was suggested, which could lead to the formation of vesicular lesions [159]. The vesicular lesion has no relation with antiviral drugs and any other COVID-19 therapies. This manifestation may be a helpful factor in diagnosing COVID-19 [161].

5- Petechiae/Purpura: Petechiae are small patches of skin, less than 2 mm in diameter, and if the lesion is more than 2 mm in diameter, it is called purpura [162-163]. Petechiae and purpura are the least prevalent skin manifestations associated with COVID-19. According to previous studies, petechiae have been observed in only 3% of patients. This complication was observed after systemic symptoms, mostly in middle-aged patients with severe disease. The proposed pathogenesis for this complication is inflammatory thrombogenic vasculopathy of the skin [164].

6- Livedoid lesions: Livedoid vasculopathy is a permanent or temporary skin manifestation typically characterized by a reddish-blue or purple grid color change [165]. These conditions are usually followed by vascular damage to the skin, decreased skin blood flow, and reduced oxygenated skin hemoglobin levels. Livedoid is one of the least common skin manifestations seen in COVID-19 patients.

Out of 375 participants in a study, only 6% showed different types and patterns of livedoid manifestations. This lesion is typically observed on the trunk, elbow flexor surface, distal hand part, and distal leg. These manifestations often coincide with others and are more common in elderly patients with severe infections. On average, this condition lasts for nine days. Among all skin manifestations observed in COVID-19 patients, those with livedoid lesions had the highest mortality rate [151].

One theory regarding the pathology of the cutaneous manifestations seen in some patients with COVID-19 is an increase in blood coagulation. A retrospective study of 83 patients who died from COVID-19 showed elevated levels of the D-dimer metabolite and fibrin and longer prothrombin times. Disseminated intravascular coagulation (DIC) induced severe COVID-19, possibly associated with mild and concomitant reticulosis. Also, the production of microthrombosis by inflammatory cytokines or virus entry into the cell through ACE2 receptors could be related to the reticularis [166, 167].

Effects on the endocrine glands (Pituitary-adrenal axis)

The hypothalamic-pituitary-adrenal (HPA) axis plays a crucial role in coping with stress. Studies have speculated that the SARS virus could affect this hormonal axis through various mechanisms, demonstrating the virus in some deceased patients' adrenal and pituitary glands [168]. A study in 2004 showed that the SARS virus expresses an amino acid sequence that mimics ACTH to block the immune response. Interfering with ACTH function can increase inflammatory cytokines [169]. Examination of 61 patients with invasive SARS found that 3.39% had hypocortisolism, while 83.3% had central adrenal dysfunction [168]. This indicated that adrenal dysfunction was a late outcome in SARS that appeared secondary to pituitary or hypothalamic injury [163].

Effects on the hypothalamic-pituitary-thyroid axis

Limited information is available on the effect of the SARS virus strain on thyroid function. However, some SARS patients have exhibited central hypothyroidism due to hypothalamic-pituitary dysfunction. Thyroid damage in SARS patients has been associated with decreased thyroid hormone and calcitonin levels and direct damage to thyroid tissue [168, 170]. According to some scientists, there was a decrease in TSH levels in some patients following SARS. In the pituitary gland of these patients, a general reduction of cells and a decrease in TSH-producing cells were reported [171]. While there is currently little evidence that COVID-19 directly affects the thyroid gland, patients with COVID-19 should still be screened for possible changes in thyroid function because

[Downloaded from jommid.pasteur.ac.ir on 2026-01-29]

[DOI: 10.52547/JoMMID.11.1.1]

the virus can damage organs by inducing autoimmunity [172].

Effects on the hypothalamic-pituitary-gonadal axis

Effects on Female Gonads. There is limited research on the effect of the COVID-19 virus on the female reproductive system. However, a recent study explored the possible mechanisms of its impact. According to this study, the expression of the ACE2 gene was increased in oocytes, ovaries, uterus, and vagina (Fig. 5) [173-175].

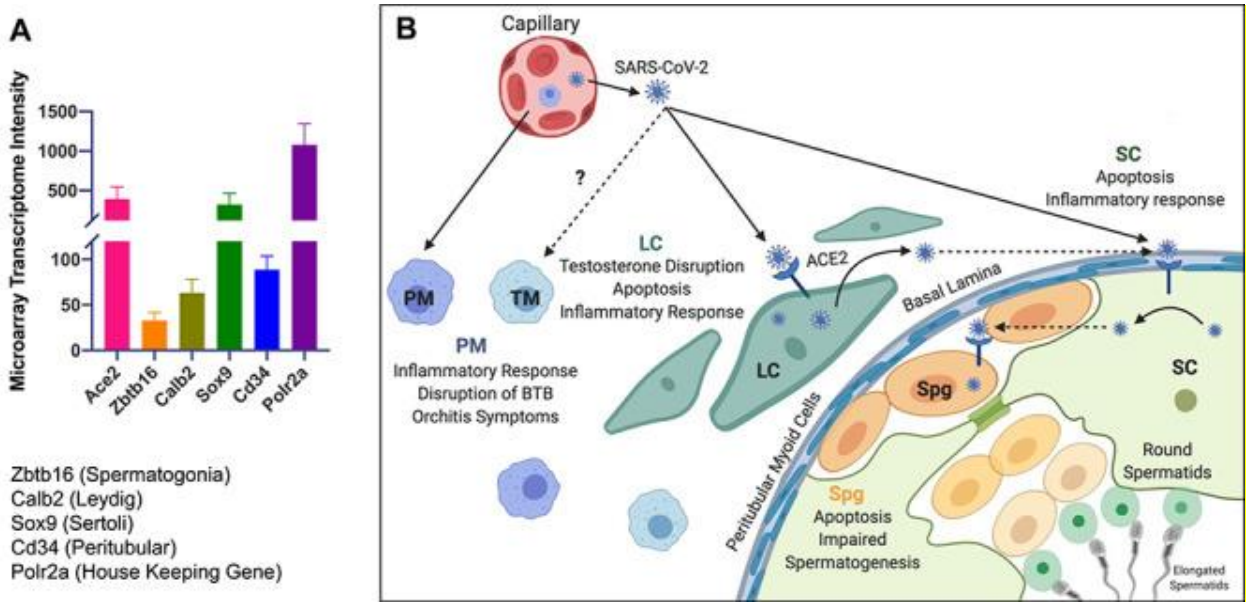

Fig. 5. (A) Comparison of ACE2 and cell-specific gene expression in normal adult human testes (n = 3) using microarray profiling assay. It shows the average (with standard error of the mean) intensity values of target genes, including ACE2 (angiotensin I converting enzyme 2), Zbtb16 (zinc finger and BTB domain containing 16; Plzf), Calb2 (calbindin 2; Calretinin), Sox9 (SRY-box transcription factor 9), Cd34, and house-keeping Polr2a (RNA polymerase II subunit A). (B) Hypothetical model of SARS-CoV-2 testicular infection based on data from other coronaviruses. ACE2 expressing LC in the interstitium is one of the targets of cell-free SARS-CoV-2 infection that leads to LC dysfunction, including impaired steroidogenesis, inflammatory response, and/or apoptosis. In addition to the interstitial Leydig cells, SARS-CoV-2 can also infect ACE2-expressing cells of the seminiferous tubules, including Sertoli cells (SC) and spermatogonia cells (Spg). This infection may cause the production of inflammatory cytokines, transient disruption of the blood-testis barrier, and depletion of germ cells, ultimately leading to impaired spermatogenesis. A SARS-CoV-2 infection-associated inflammatory response in the testes may result in increased recruitment of the peripheral immune cells, including peripheral macrophages (PM) and virus-specific T cells (not shown here), that may facilitate virus clearance. While the virus may not directly infect testicular macrophages (TM), it can suppress the inflammatory response and limit testicular damage [173].

Effects on Male Gonads. ACE2 mRNA in the testes is primarily expressed in Sertoli cells, Leydig, and during spermatogenesis [24]. The expression of this gene in these organs is probably maximal [176]. On the other hand, *TMPRSS2*, one of the critical factors enabling virus entry, is also present in the testis [177]. The SARS virus can cause orchitis and extensive destruction of testicular cells. Due to the 76% similarity between the SARS virus and COVID-19's amino acid sequences, COVID-19 may affect affects sperm production and testosterone secretion as well [178].

COVID-19 infection can destroy the blood-testis barrier due to illness and inflammation, increasing the risk of virus entry. Several reports have confirmed severe pain and discomfort in the testicles in patients with COVID-19, with one piece of information explicitly confirming epididymitis [177, 179, 180]. A 2020 study measured LH, FSH, and testosterone levels. The pattern of elevated LH and no significant change in testosterone disproves the hypothesis of COVID-19's effect on the hypothalamus, pituitary, and Leydig cells. In addition, FSH levels remained stable during the experiment compared to the healthy group. This test defect could result from direct testicular damage or an indirect inflammatory/immune response in the testis [181, 182].

Most studies analyzing the semen of patients with COVID-19 did not observe any trace of the virus's presence, either during the disease or after recovery [183]. In a study, in the semen samples of a few patients, the COVID-19 virus was seen. Patients with moderate to severe infections had significant abnormalities in sperm quality, such as sperm concentration, total sperm count per ejaculation, and sperm motility, compared with mildly infected patients and the healthy group. In summary, this virus in a few patients is observed, and it changes the quality of sperm [184].

[Downloaded from jommid.pasteur.ac.ir on 2026-01-29]

[DOI: 10.52547/JoMMID.11.1.1]

Effects on pancreas

Pancreatic ACE2 expression is prominent in the ductal epithelium and the microvasculature but is rare in endocrine cells [158]. Autopsies of COVID-19 patients revealed multiple thrombotic lesions expressing SARS-COV-2 nucleocapsid protein confined to the ducts of the pancreas. Virus particles in the kidneys have been observed in the autopsies of non-transplant patients 24-48 h

after death.

Furthermore, they evaluated the expression patterns of other genes related to SARS-COV-2, such as *TMPRSS4*, *TMPRSS11D*, *CTSL*, and *ADAM17*. The results showed that *CTSL* and *ADAM17* were more abundant in α- and β-cells while *TMPRSS4* had low levels in endocrine cells, and the expression level of *TMPRSS11D* was also low in most cell types of the pancreas [181]. A study reported the first case of COVID-19 infection in pancreatic transplant recipients, and to date, there have been no other reports of COVID-19 in pancreatic transplant recipients (PT) [183].

As discussed in this paper, the SARS-COV-2 virus can enter various organs, leading to cell death and tissue damage. The upper respiratory tract is the primary target of COVID-19. The virus can cause acute pulmonary inflammation, pulmonary edema, ARDS, and endothelial dysfunction in the lung as the primary target organs. Reports indicate that this virus can also enter other tissues and organs and cause complications. Mechanisms related to angiotensin II receptors and cytokine pathways can cause acute pulmonary inflammation, pulmonary edema, acute respiratory distress syndrome, vascular endothelial dysfunction, pulmonary embolism in the lungs, and heart failure. In addition, the COVID-19 virus can cause other inflammatory complications in other organs, such as the heart, gastrointestinal tract, CNS, liver, kidney, glands, pancreas, and skin. However, infection complications in the glands and pancreas have not yet been confirmed. Also, viral infection-induced liver damage is typically mild and reversible. In addition, skin manifestations may be due to drug use during infection or disease complications. Reports indicate that COVID-19 infection can cause gastrointestinal symptoms such as diarrhea, vomiting, and abdominal pain. Several reports have shown mild and transient liver damage, polyneuropathy, encephalitis, stroke, acute renal failure, hypocortisolism, and hypothalamus and pituitary system damage as potential complications of COVID-19. In addition, COVID-19 can cause cutaneous manifestations such as rash, urticaria, maculopapular lesions, chilblains, petechial purpura, and scalopathy. Studying these effects is necessary to consider these different symptoms in diagnosing and treating COVID-19. The pathological effects of COVID-19 on body organs examined in this paper are summarised in Table 2.

Table 2. Pathological effects of COVID-19 on body organs

Pathological effects	References
Pulmonary effects	[34-49]
Cardiac effects	[50-68]
Myocarditis	[54, 69-88]
Effects on blood pressure	[54, 58, 72, 89-91]
Effects on blood vessels	[72-79, 84-103, 45]
Gastrointestinal symptoms	[104]
Liver effects	[105]
The Central Nervous System (CNS) effects	[106-118]
SARS-COV-2 entry and action on the CNS	[119-138, 50, 110]
Kidney effects	[128, 139-149]
Skin manifestations	[150-167]
Effects on the endocrine glands (Pituitary-adrenal axis)	[168-169]
Effects on the hypothalamic-pituitary-thyroid axis	[168, 170-172]
Effects on the hypothalamic-pituitary-gonadal axis	Female gonads: [173-175] Male gonads: [24, 176-184]
Effects on pancreas	[181, 183]

ACKNOWLEDGMENT

No funding was received for this study.

CONFLICT OF INTEREST

The authors declare no conflicts of interest associated with this manuscript.

REFERENCES

1. Wang Z, Xu X. scRNA-seq profiling of human testes reveals the presence of the ACE2 receptor, a target for SARS-CoV-2 infection in spermatogonia, Leydig and Sertoli cells. Cells. 2020; 9 (4): 920.

2. Organization WH. World Health Organization coronavirus disease 2019 (COVID-19) situation report.

3. Peng X, Xu X, Li Y, Cheng L, Zhou X, Ren B. Transmission routes of 2019-nCoV and controls in dental practice. Int J Oral Sci. 2020; 12 (1): 1-6.

4. Tavakoli A, Vahdat K, Keshavarz M. Novel coronavirus disease 2019 (COVID-19): an emerging infectious disease in the 21st century. ISMJ. 2020; 22 (6): 432-50.

5. Van Doremalen N, Bushmaker T, Morris DH, Holbrook MG, Gamble A, Williamson BN, et al. Aerosol and surface stability of SARS-CoV-2 as compared with SARS-CoV-1. N Engl J Med. 2020; 382 (16): 1564-7.

[Downloaded from jommid.pasteur.ac.ir on 2026-01-29]

[DOI: 10.52547/JoMMID.11.1.1]

6. Guan W-j, Ni Z-y, Hu Y, Liang W-h, Ou C-q, He J-x, et al. Clinical characteristics of 2019 novel coronavirus infection in China. MedRxiv. 2020.

7. Gerami A, Dadgar S, Rakhshan V, Jannati P, Sobouti F. Displacement and force distribution of splinted and tilted mandibular anterior teeth under occlusal loads: an in silico 3D finite element analysis. Prog Orthod. 2016;17 (1): 16.

8. Control CfD, Prevention. People who are at higher risk for severe illness, https://www.cdc.gov/ coronavirus/2019-ncov/need-extra-precautions/people-with-medical-conditions.html, 2020.

9. Control CfD, Prevention. Symptoms of coronavirus. Available at:(Accessed April 21, 2020) https://www. cdc. gov/coronavirus/2019-ncov/symptoms-testing/symptoms. html View in Article. 2020.

10. Buja LM, Wolf D, Zhao B, Akkanti B, McDonald M, Lelenwa L, et al. Emerging Spectrum of Cardiopulmonary Pathology of the Coronavirus Disease 2019 (COVID-19): Report of three Autopsies from Houston, Texas and Review of Autopsy Findings from other United States Cities. Cardiovas Pathol. 2020; 48: 107233.

11. Bayarri-Olmos R, Johnsen LB, Idorn M, Reinert L-S, Rosbjerg A, Vang S, et al. The alpha/B.1.1.7 SARS-CoV-2 variant exhibits significantly higher affinity for ACE-2 and requires lower inoculation doses to cause disease in K18-hACE2 mice. Elife. 2021; 10: e70002.

12. Natekar JP, Pathak H, Stone S, Kumari P, Sharma S, Auroni TT, et al. Differential Pathogenesis of SARS-CoV-2 Variants of Concern in Human ACE2-Expressing Mice. Viruses. 2022; 14 (6): 1139.

13. Al-Awwal N, Dweik F, Mahdi S, El-Dweik M, Anderson S-H. A Review of SARS-CoV-2 Disease (COVID-19): Pandemic in Our Time. Pathogens. 2022; 11 (3): 368.

14. Ortega M-A, García-Montero C, Fraile-Martinez O, Colet P, Baizhaxynova A, Mukhtarova K, et al. Recapping the Features of SARS-CoV-2 and Its Main Variants: Status and Future Paths. J Pers Med. 2022; 12 (6): 995.

15. Zhou D, Dejnirattisai W, Supasa P, Liu C, Mentzer A-J, Ginn H-M, et al. Evidence of escape of SARS-CoV-2 variant B.1.351 from natural and vaccine-induced sera. Cell. 2021; 184 (9): 2348-61.

16. Pan T, Chen R, He X, Yuan Y, Deng X, Li R, et al. Infection of wild-type mice by SARS-CoV-2 B.1.351 variant indicates a possible novel cross-species transmission route. Signal Transduct Target Ther. 2021; 6 (1): 420.

17. Banho CA, Sacchetto L, Campos GRF, Bittar C, Possebon FS, Ullmann LS, et al. Impact of SARS-CoV-2 Gamma lineage introduction and COVID-19 vaccination on the epidemiological landscape of a Brazilian city. Commun Med. 2022; 2: 41.

18. Saberiyan M, Karimi E, Khademi Z, Movahhed P, Safi A, Mehri-Ghahfarrokhi A. SARS-CoV-2: phenotype, genotype, and characterization of different variants. Cell Mol Biol Lett. 2022; 27 (1): 50.

19. Carroll T, Fox D, van Doremalen N, Ball E, Morris MK, Sotomayor-Gonzalez A, et al. The B.1.427/1.429 (epsilon) SARS-CoV-2 variants are more virulent than ancestral B.1 (614G) in Syrian hamsters. PLOS Pathog. 2022; 18 (2): e1009914.

20. Khan A, Khan T, Ali S, Aftab S, Wang Y, Qiankun W, et al. SARS-CoV-2 new variants: Characteristic features and impact on the efficacy of different vaccines. Biomed Pharmacother. 2021; 143: 112176.

21. Tao K, Tzou PL, Nouhin J, Gupta RK, de Oliveira T, Pond SLK, et al. The biological and clinical significance of emerging SARS- CoV-2 variants. Nat Rev Genet. 2021; 22 (12): 757-73.

22. Lekana-Douki SE, N'dilimabaka N, Levasseur A, Colson P, Andeko JC, Minko OZ, et al. Screening and Whole Genome Sequencing of SARS-CoV-2 Circulating During the First Three Waves of the COVID-19 Pandemic in Libreville and the Haut-Ogooué Province in Gabon. Front Med. 2022; 9: 877391.

23. Hwang Y-C, Lu R-M, Su S-C, Chiang P-Y, Ko S-H, Ke F-Y, et al. Monoclonal antibodies for COVID-19 therapy and SARS-CoV-2 detection. J Biomed Sci. 2022; 29 (1): 1.

24. Yang W, Greene SK, Peterson ER, Li W, Mathes R, Graf L, et al. Epidemiological characteristics of the B.1 1.526 SARS-CoV-2 variant. Sci Adv. 2022; 8 (4):eabm0300.

25. Yadav P, Mohandas S, Shete AM, Nyayanit DA, Gupta N, Patil DY, et al. SARS-CoV-2 Kappa Variant Shows Pathogenicity in a Syrian Hamster Model. Vector Borne Zoonotic Dis. 2022; 22 (5): 289-96.

26. Blann AD, Heitmar R. SARS-CoV-2 and COVID-19: A Narrative Review. Br J Biomed Sci. 2022; 79: 10426.

27. Mohandas S, Yadav PD, Shete A, Nyayanit D, Sapkal G, Lole K, et al. SARS-CoV-2 Delta Variant Pathogenesis and Host Response in Syrian Hamsters. Viruses. 2021; 13 (9): 1773.

28. Kumar A, Parashar R, Kumar S, Faiq MA, Kumari C, Kulandhasamy M, et al. Emerging SARS-CoV-2 variants can potentially break set epidemiological barriers in COVID-19, J Med Virol. 2022; 94 (4): 1300-14.

29. Yadav P, Mohandas S, Sarkale P, Nyayanit D, Shete A, Sahay R, et al. Isolation of SARS-CoV-2 B.1.1.28.2 (P2) variant and pathogenicity comparison with D614G variant in hamster model. J Infect Public Health. 2022; 15 (2): 164-71.

30. Nielsen MC, Machado RRG, Mitchell BM, McConnell AJ, Saada NI, Weaver SC, et al. A Comparison of Seegene Technologies Novaplex SARS-CoV-2 Variants I, II, and IV Assays with Spike Gene Sequencing for Detection of Known Severe Acute Respiratory Syndrome Coronavirus 2 Variants. J Mol Diagn. 2022; 24 (5): 455-61.

31. Al-Awwal N, Dweik F, Mahdi S, El-Dweik M, Anderson SH. A Review of SARS-CoV-2 Disease (COVID-19): Pandemic in Our Time. Pathogens. 2022; 11 (3): 368.

32. Zhang J, Chen N, Zhao D, Zhang J, Hu Z, Tao Z. Clinical Characteristics of COVID-19 Patients Infected by the Omicron Variant of SARS-CoV-2. Front Med. 2022; 9: 912367.

33. Armando F, Beythien G, Kaiser FK, Allnoch L, Heydemann L, Rosiak M, et al. SARS-CoV-2 Omicron variant causes mild pathology in the upper and lower respiratory tract of hamsters. Nat Commun. 2022; 13 (1): 3519.

34. Khan S, Siddique R, Shereen MA, Ali A, Liu J, Bai Q, et al. Emergence of a novel coronavirus, severe acute respiratory syndrome coronavirus 2: biology and therapeutic options. J Clin Microbiol. 2020; 58 (5): e00187-20.

[Downloaded from jommid.pasteur.ac.ir on 2026-01-29]

[DOI: 10.52547/JoMMID.11.1.1]

35. Jin Y, Yang H, Ji W, Wu W, Chen S, Zhang W, et al. Virology, epidemiology, pathogenesis, and control of COVID-19. Viruses. 2020;1 2 (4): 372.

36. Gosain R, Abdou Y, Singh A, Rana N, Puzanov I, Ernstoff MS. COVID-19 and cancer: a comprehensive review. Curr Oncol Rep. 2020; 22 (5): 53.

37. Fung TS, Liu DX. Human coronavirus: host-pathogen interaction. Annu. Rev. Microbiol. 2019; 73: 529-57.

38. Calabrò L, Peters S, Soria J-C, Di Giacomo AM, Barlesi F, Covre A, et al. Challenges in lung cancer therapy during the COVID-19 pandemic. Lancet Respir Med. 2020; 8 (6): 542-4.

39. Hirsch FR, Scagliotti GV, Mulshine JL, Kwon R, Curran Jr WJ, Wu Y-L, et al. Lung cancer: current therapies and new targeted treatments. Lancet. 2017; 389 (10066): 299-311.

40. Zhou S, Wang Y, Zhu T, Xia L. CT features of coronavirus disease 2019 (COVID-19) pneumonia in 62 patients in Wuhan, China. Am J Roentgenol. 2020; 214 (6): 1287-94.

41. Yu PS, Chan JW, Lau RW, Ng CS. Screening-detected pure ground-glass opacities: malignant potential beyond conventional belief? Transl Lung Cancer Rese. 2020; 9 (3): 816-8.

42. Wang K, Gheblawi M, Oudit GY. Angiotensin converting enzyme 2: a double-edged sword. Circulation. 2020; 142 (5): 426-8.

43. Milne S, Yang CX, Timens W, Bossé Y, Sin DD. SARS-CoV-2 receptor ACE2 gene expression and RAAS inhibitors. Lancet Respir Med. 2020; 8 (6): 50-1.

44. Ackermann M, Verleden SE, Kuehnel M, Haverich A, Welte T, Laenger F, et al. Pulmonary vascular endothelialitis, thrombosis, and angiogenesis in COVID-19. N Engl J Med. 2020; 383 (2): 120-8.

45. Ullah W, Saeed R, Sarwar U, Patel R, Fischman DL. COVID-19 complicated by acute pulmonary embolism and right-sided heart failure. JACC Case Reports. 2020; 2 (9): 1379-82.

46. Gallo G, Sammarco G, Fulginiti S, Vescio G, COVIDSurg C. Mortality and pulmonary complications in patients undergoing surgery with perioperative SARS-CoV-2 infection: an international cohort study. Lacent. 2020; 396 (10243): 27-38.

47. Whyte CS, Morrow GB, Mitchell JL, Chowdary P, Mutch NJ. Fibrinolytic abnormalities in acute respiratory distress syndrome (ARDS) and versatility of thrombolytic drugs to treat COVID-19. J Thromb Haemost. 2020; 18 (7): 1548-55.

48. Severin R, Arena R, Lavie CJ, Bond S, Phillips SA. Respiratory muscle performance screening for infectious disease management following COVID-19: a highly pressurized situation. Am J Med. 2020; 133 (9): 1025–32.

49. Paneroni M, Simonelli C, Saleri M, Bertacchini L, Venturelli M, Troosters T, et al. Muscle strength and physical performance in patients without previous disabilities recovering from COVID-19 pneumonia. Am J Phys Med Rehabil. 2021; 100 (2): 105-9.

50. Turner AJ, Hiscox JA, Hooper NM. ACE2: from vasopeptidase to SARS virus receptor. Trends Pharmacol Sci. 2004; 25 (6): 291-4.

51. Richardson S, Hirsch JS, Narasimhan M, Crawford JM, McGinn T, Davidson KW, et al. Presenting characteristics, comorbidities, and outcomes among 5700 patients hospitalized with COVID-19 in the New York City area. JAMA. 2020; 323 (20): 2052-9.

52. Guo T, Fan Y, Chen M, Wu X, Zhang L, He T, et al. Cardiovascular implications of fatal outcomes of patients with coronavirus disease 2019 (COVID-19). JAMA Cardiol. 2020; 5 (7): 811-8.

53. Guan W-j, Ni Z-y, Hu Y, Liang W-h, Ou C-q, He J-x, et al. Clinical characteristics of coronavirus disease 2019 in China. N Engl J Med. 2020; 382 (18): 1708-20.

54. Zhou F, Yu T, Du R, Fan G, Liu Y, Liu Z, et al. Clinical course and risk factors for mortality of adult inpatients with COVID-19 in Wuhan, China: a retrospective cohort study. Lancet. 2020; 395 (10229): 1054-62.

55. Vaduganathan M, Vardeny O, Michel T, McMurray JJ, Pfeffer MA, Solomon SD. Renin–angiotensin–aldosterone system inhibitors in patients with COVID-19. N Engl J Med. 2020; 382 (17): 1653-9.

56. Dostal DE, Baker KM. The cardiac renin-angiotensin system: conceptual, or a regulator of cardiac function? Circ Res. 1999; 85 (7): 643-50.

57. Gemmati D, Bramanti B, Serino ML, Secchiero P, Zauli G, Tisato V. COVID-19 and Individual Genetic Susceptibility/Receptivity: Role of ACE1/ACE2 Genes, Immunity, Inflammation and Coagulation. Might the Double X-Chromosome in Females Be Protective against SARS-CoV-2 Compared to the Single X-Chromosome in Males? Int J Mol Sci. 2020; 21 (10): 3474.

58. Zores F, Rebeaud ME. COVID and the renin-angiotensin system: are hypertension or its treatments deleterious? Front Cardiovasc Med. 2020; 7: 71.

59. Fraga-Silva RA, Sorg BS, Wankhede M, deDeugd C, Ferreira AJ, Jun Y, et al. ACE2 Activation Promotes Antithrombotic Activity. Mol Med. 2010; 16 (5-6): 210-5.

60. Olkowicz M, Chlopicki S, Smolenski RT. Perspectives for angiotensin profiling with liquid chromatography/mass spectrometry to evaluate ACE/ACE2 balance in endothelial dysfunction and vascular pathologies. Pharmacol Rep. 2015; 67 (4): 778-85.

61. Epelman S, Tang WW, Chen SY, Van Lente F, Francis GS, Sen S. Detection of soluble angiotensin-converting enzyme 2 in heart failure: insights into the endogenous counter-regulatory pathway of the renin-angiotensin-aldosterone system. J Am Coll Cardiol. 2008; 52 (9): 750-4.

62. Oudit GY, Pfeffer MA. Plasma angiotensin-converting enzyme 2: novel biomarker in heart failure with implications for COVID-19. Eur Heart J. 2020; 41 (19): 1818-20.

63. Zhang H, Penninger JM, Li Y, Zhong N, Slutsky AS. Angiotensin-converting enzyme 2 (ACE2) as a SARS-CoV-2 receptor: molecular mechanisms and potential therapeutic target. Intensive Care Med. 2020; 46 (4): 586-90.

64. Chen L, Liu W, Zhang Q, Xu K, Ye G, Wu W, et al. RNA based mNGS approach identifies a novel human coronavirus from two individual pneumonia cases in 2019 Wuhan outbreak. Emerg Microbes Infect. 2020; 9 (1): 313-9.

65. Wu A, Peng Y, Huang B, Ding X, Wang X, Niu P, et al. Genome composition and divergence of the novel coronavirus

[Downloaded from jommid.pasteur.ac.ir on 2026-01-29]

[DOI: 10.52547/JoMMID.11.1.1]

(2019-nCoV) originating in China. Cell Host Microbe. 2020; 27 (3): 325-8.

66. Wang D, Hu B, Hu C, Zhu F, Liu X, Zhang J, et al. Clinical characteristics of 138 hospitalized patients with 2019 novel coronavirus–infected pneumonia in Wuhan, China. Jama. 2020; 323 (11): 1061-9.

67. Zheng Y, Ma Y, Zhang J, Xie X. COVID-19 and the cardiovascular system. Nat Rev Cardiol. 2020; 17 (5): 259-260.

68. Pellicori P, Zhang J, Cuthbert J, Urbinati A, Shah P, Kazmi S, et al. High-sensitivity C-reactive protein in chronic heart failure: patient characteristics, phenotypes, and mode of death. Cardiovasc Res. 2020; 116 (1): 91-100.

69. Cooper Jr LT. Myocarditis. N Engl J Med. 2009; 360 (15): 1526-38.

70. Siddiqi HK, Mehra MR. COVID-19 illness in native and immunosuppressed states: A clinical–therapeutic staging proposal. J Heart Lung Transplant. 2020; 39 (5): 405-7.

71. Shi S, Qin M, Shen B, Cai Y, Liu T, Yang F, et al. Association of cardiac injury with mortality in hospitalized patients with COVID-19 in Wuhan, China. JAMA Cardiol. 2020; 5 (7): 802-10.

72. Grasselli G, Zangrillo A, Zanella A, Antonelli M, Cabrini L, Castelli A, et al. Baseline characteristics and outcomes of 1591 patients infected with SARS-CoV-2 admitted to ICUs of the Lombardy Region, Italy. JAMA. 2020; 323 (16): 1574-81.

73. Inciardi RM, Lupi L, Zaccone G, Italia L, Raffo M, Tomasoni D, et al. Cardiac involvement in a patient with coronavirus disease 2019 (COVID-19). JAMA Cardiol. 2020; 5 (7): 819-24.

74. Wang CJ, Ng CY, Brook RH. Response to COVID-19 in Taiwan: big data analytics, new technology, and proactive testing. Jama. 2020; 323 (14): 1341-2.

75. Tersalvi G, Vicenzi M, Calabretta D, Biasco L, Pedrazzini G, Winterton D. Elevated troponin in patients with Coronavirus Disease 2019 (COVID-19): possible mechanisms. J Card Fail. 2020; 26 (6): 470-5.

76. Doyen D, Moceri P, Ducreux D, Dellamonica J. Myocarditis in a patient with COVID-19: a cause of raised troponin and ECG changes. Lancet. 2020; 395 (10235): 1516.

77. Kochi AN, Tagliari AP, Forleo GB, Fassini GM, Tondo C. Cardiac and arrhythmic complications in patients with COVID-19. J Cardiovasc Electrophysiol. 2020;31 (5): 1003-8.

78. Hu H, Ma F, Wei X, Fang Y. Coronavirus fulminant myocarditis treated with glucocorticoid and human immunoglobulin. Eur Heart J 2020; 42 (2): 206.

79. Lakkireddy DR, Chung MK, Gopinathannair R, Patton KK, Gluckman TJ, Turagam M, et al. Guidance for Cardiac Electrophysiology During the COVID-19 Pandemic from the Heart Rhythm Society COVID-19 Task Force; Electrophysiology Section of the American College of Cardiology; and the Electrocardiography and Arrhythmias Committee of the Council on Clinical Cardiology, American Heart Association. Circulation. 2020; 141 (21): e823-e31.

80. Puntmann VO, Carerj ML, Wieters I, Fahim M, Arendt C, Hoffmann J, et al. Outcomes of cardiovascular magnetic resonance imaging in patients recently recovered from coronavirus disease 2019 (COVID-19). JAMA Cardiol. 2020; 5 (11): 1265-73.

81. Lindner D, Fitzek A, Bräuninger H, Aleshcheva G, Edler C, Meissner K, et al. Association of cardiac infection with SARS-CoV-2 in confirmed COVID-19 autopsy cases. JAMA Cardiol. 2020; 5 (11): 1281-5.

82. Sharma A, Garcia G, Arumugaswami V, Svendsen CN. Human iPSC-Derived Cardiomyocytes are Susceptible to SARS-CoV-2 Infection. Cell Rep Med. 2020; 1 (4): 100052.

83. Colivicchi F, Di Fusco SA, Magnanti M, Cipriani M, Imperoli G. The impact of the coronavirus disease-2019 pandemic and Italian lockdown measures on clinical presentation and management of acute heart failure. J Card Fail. 2020; 26 (6): 464-5.

84. Chen C, Zhou Y, Wang DW. SARS-CoV-2: a potential novel etiology of fulminant myocarditis. Herz. 2020; 45 (3): 230-32.

85. Zheng Y-Y, Ma Y-T, Zhang J-Y, Xie X. COVID-19 and the cardiovascular system. Nat Rev Cardiol. 2020; 17 (5): 259-60.

86. Błyszczuk P. Myocarditis in humans and in experimental animal models. Front Cardiovasc Med. 2019; 6: 64.

87. Guzik TJ, Mohiddin SA, Dimarco A, Patel V, Savvatis K, Marelli-Berg FM, et al. COVID-19 and the cardiovascular system: implications for risk assessment, diagnosis, and treatment options. Cardiovasc Res. 2020; 116 (10): 1666-87.

88. Wongchana W, Palaga T. Direct regulation of interleukin-6 expression by Notch signaling in macrophages. Cell Mol Immunol. 2012; 9 (2): 155-62.

89. Samidurai A, Das A. Cardiovascular Complications Associated with COVID-19 and Potential Therapeutic~ Strategies. Int J Mol Sci. 2020; 21 (18): 6790.

90. Fang L, Karakiulakis G, Roth M. Are patients with hypertension and diabetes mellitus at increased risk for COVID-19 infection? Lancet Respir Med. 2020; 8 (4): e21.

91. Sun M, Yang J, Sun Y, Su G. Inhibitors of RAS might be a good choice for the therapy of COVID-19 pneumonia. Zhonghua Jie He He Hu Xi Za Zhi. 2020; 43 (0): E014-.

92. Furuhashi M, Moniwa N, Mita T, Fuseya T, Ishimura S, Ohno K, et al. Urinary angiotensin-converting enzyme 2 in hypertensive patients may be increased by olmesartan, an angiotensin II receptor blocker. Am J Hypertens. 2015; 28 (1): 15-21.

93. Jarcho JA, Ingelfinger JR, Hamel MB, D'Agostino Sr RB, Harrington DP. Inhibitors of the renin–angiotensin–aldosterone system and COVID-19. N Engl J Med. 2020; 382 (25): 2462-4.

94. Mancia G, Rea F, Ludergnani M, Apolone G, Corrao G. Renin–angiotensin–aldosterone system blockers and the risk of COVID-19. N Engl J Med. 2020; 382 (25): 2431-40.

95. Young BE, Ong SWX, Kalimuddin S, Low JG, Tan SY, Loh J, et al. Epidemiologic features and clinical course of patients infected with SARS-CoV-2 in Singapore. JAMA. 2020; 323 (15): 1488-94.

96. Becker RC. COVID-19 update: COVID-19-associated coagulopathy. J. Thromb Thrombolysis. 2020; 50 (1): 54-67.

[Downloaded from jommid.pasteur.ac.ir on 2026-01-29]

[DOI: 10.52547/JoMMID.11.1.1]

97. Bompard F, Monnier H, Saab I, Tordjman M, Abdoul H, Fournier L, et al. Pulmonary embolism in patients with Covid-19 pneumonia. Eur Respir J. 2020; 56 (1): 2001365.

98. Criel M, Falter M, Jaeken J, Van Kerrebroeck M, Lefere I, Meylaerts L, et al. Venous thromboembolism in SARS-CoV-2 patients: only a problem in ventilated ICU patients, or is there more to it? Eur Respir J. 2020; 56 (1): 2001201.

99. Danzi GB, Loffi M, Galeazzi G, Gherbesi E. Acute pulmonary embolism and COVID-19 pneumonia: a random association? Eur Heart J. 2020; 41 (19): 1858.

100. Dolhnikoff M, Duarte-Neto AN, de Almeida Monteiro RA, da Silva LFF, de Oliveira EP, Saldiva PHN, et al. Pathological evidence of pulmonary thrombotic phenomena in severe COVID-19. J Thromb Haemost. 2020; 18 (6): 1517-19.

101. Poissy J, Goutay J, Caplan M, Parmentier E, Duburcq T, Lassalle F, et al. Pulmonary embolism in patients with COVID-19: awareness of an increased prevalence. Circulation. 2020; 142 (2): 184-6.

102. Flammer AJ, Anderson T, Celermajer DS, Creager MA, Deanfield J, Ganz P, et al. The assessment of endothelial function: from research into clinical practice. Circulation. 2012; 126 (6): 753-67.

103. Ferrario CM, Jessup J, Chappell MC, Averill DB, Brosnihan KB, Tallant EA, et al. Effect of angiotensin-converting enzyme inhibition and angiotensin II receptor blockers on cardiac angiotensin-converting enzyme 2. Circulation. 2005; 111 (20): 2605-10.

104. Bonetti PO, Lerman LO, Lerman A. Endothelial dysfunction: a marker of atherosclerotic risk. Arterioscler. Thromb Vasc Biol. 2003; 23 (2): 168-75.

105. Yang R-X, Zheng R-D, Fan J-G. Etiology and management of liver injury in patients with COVID-19. World J. Gastroenterol. 2020; 26 (32): 4753-62.

106. Al-Obaidi MJ, Bahadoran A, Wang S, Manikam R, Raju CS, Sekaran S. Disruption of the blood brain barrier is vital property of neurotropic viral infection of the central nervous system. Acta Virol. 2018; 62 (1): 16-27.

107. Michalicova A, Bhide K, Bhide M, Kovac A. How viruses infiltrate the central nervous system. Acta Virol. 2017; 61 (4): 393-400.

108. Zhang T, Wu Q, Zhang Z. Probable pangolin origin of SARS-CoV-2 associated with the COVID-19 outbreak. Curr Biol. 2020; 30 (7): 1346-51.

109. Hung EC, Chim SS, Chan PK, Tong YK, Ng EK, Chiu RW, et al. Detection of SARS coronavirus RNA in the cerebrospinal fluid of a patient with severe acute respiratory syndrome. Clin Chem. 2003; 49 (12): 2108-9.

110. Netland J, Meyerholz DK, Moore S, Cassell M, Perlman S. Severe acute respiratory syndrome coronavirus infection causes neuronal death in the absence of encephalitis in mice transgenic for human ACE2. J Virol. 2008; 82 (15): 7264-75.

111. Tsai L, Hsieh S, Chang Y. Neurological manifestations in severe acute respiratory syndrome. Acta Neurol Taiwan. 2005; 14 (3): 113-9.

112. Zhang Q, Ding Y, Hou J, He L, Huang Z, Wang H, et al. Detection of severe acute respiratory syndrome (SARS)-associated coronavirus RNA in autopsy tissues with in situ hybridization. Di Yi Jun Yi Da Xue Xue Bao. 2003; 23 (11): 1125-7.

113. Gu J, Gong E, Zhang B, Zheng J, Gao Z, Zhong Y, et al. Multiple organ infection and the pathogenesis of SARS. J Exp Med. 2005; 202 (3): 415-24.

114. Kim J-E, Heo J-H, Kim H-o, Song S-h, Park S-S, Park T-H, et al. Neurological complications during treatment of middle east respiratory syndrome. J Clin Neurol. 2017; 13 (3): 227-33.

115. Huang C, Wang Y, Li X, Ren L, Zhao J, Hu Y, et al. Clinical features of patients infected with 2019 novel coronavirus in Wuhan, China. Lancet. 2020; 395 (10223): 497-506.

116. Poyiadji N, Shahin G, Noujaim D, Stone M, Patel S, Griffith B. COVID-19–associated acute hemorrhagic necrotizing encephalopathy: CT and MRI features. Radiology. 2020; 296 (2): 119-20.

117. Mao L, Jin H, Wang M, Hu Y, Chen S, He Q, et al. Neurologic manifestations of hospitalized patients with coronavirus disease 2019 in Wuhan, China. JAMA neurology. 2020; 77 (6): 683- 90.

118. Zhao K, Huang J, Dai D, Feng Y, Liu L, Nie S. Acute myelitis after SARS-CoV-2 infection: a case report. MedRxiv. 2020.

119. Nemoto W, Yamagata R, Nakagawasai O, Nakagawa K, Hung W-Y, Fujita M, et al. Effect of spinal angiotensin-converting enzyme 2 activation on the formalin-induced nociceptive response in mice. Eur J Pharmacol. 2020; 872: 172950.

120. Unni SK, Růžek D, Chhatbar C, Mishra R, Johri MK, Singh SK. Japanese encephalitis virus: from genome to infectome. Microbes Infect. 2011; 13 (4): 312-21.

121. Koyuncu OO, Hogue IB, Enquist LW. Virus infections in the nervous system. Cell Host Microbe. 2013; 13 (4): 379-93.

122. Bohmwald K, Galvez N, Ríos M, Kalergis AM. Neurologic alterations due to respiratory virus infections. Front Cell Neurosci. 2018; 12: 386.

123. Abdennour L, Zeghal C, Deme M, Puybasset L. Interaction brain-lungs. Paper presented at: Ann Fr Anesth Reanim. 2012; 31 (6): 101-7.

124. Guo Y-R, Cao Q-D, Hong Z-S, Tan Y-Y, Chen S-D, Jin H-J, et al. The origin, transmission and clinical therapies on coronavirus disease 2019 (COVID-19) outbreak–an update on the status. Mil Med Res. 2020; 7 (1): 11.

125. Klein RS, Garber C, Howard N. Infectious immunity in the central nervous system and brain function. Nat Immunol. 2017; 18 (2): 132-41.

126. Mehta P, McAuley DF, Brown M, Sanchez E, Tattersall RS, Manson JJ, et al. COVID-19: consider cytokine storm syndromes and immunosuppression. Lancet. 2020; 395 (10229): 1033-4.

127. Yin C, Wang C, Tang Z, Wen Y, Zhang S, Wang B. Clinical analysis of multiple organ dysfunction syndrome in patients suffering from SARS. Zhongguo Wei Zhong Bing Ji Jiu Yi Xue. 2004; 16 (11): 646-50.

128. Li Y, Fu L, Gonzales DM, Lavi E. Coronavirus neurovirulence correlates with the ability of the virus to induce

[Downloaded from jommid.pasteur.ac.ir on 2026-01-29]

[DOI: 10.52547/JoMMID.11.1.1]

proinflammatory cytokine signals from astrocytes and microglia. J Virol. 2004; 78 (7): 3398-406.

129. Cheng Y, Luo R, Wang K, Zhang M, Wang Z, Dong L, et al. Kidney disease is associated with in-hospital death of patients with COVID-19. Kidney Int. 2020; 97 (5): 829-38.

130. Wan S, Yi Q, Fan S, Lv J, Zhang X, Guo L, et al. Characteristics of lymphocyte subsets and cytokines in peripheral blood of 123 hospitalized patients with 2019 novel coronavirus pneumonia (NCP). MedRxiv. 2020.

131. Miller AJ, Arnold AC. The renin–angiotensin system in cardiovascular autonomic control: recent developments and clinical implications. Clin Auton Res. 2019; 29 (2): 231-43.

132. Sungnak W, Bécavin C, Berg M. HCA Lung Biological Network. SARS-CoV-2 Entry Genes Are Most Highly Expressed in Nasal Goblet and Ciliated Cells within Human Airways. ArXiv. 2020; 200306122.

133. Jahanshahlu L, Rezaei N. Central nervous system involvement in COVID-19. Arch Med Res. 2020; 51 (7): 721-2.

134. Sriram K, Insel PA. Risks of ACE inhibitor and ARB usage in COVID-19: evaluating the evidence. Clin Pharmacol Ther. 2020; 108 (2): 236-41.

135. Butowt R, Bilinska K. SARS-CoV-2: olfaction, brain infection, and the urgent need for clinical samples allowing earlier virus detection. ACS Chem Neurosci. 2020; 11 (9): 1200-3.

136. Kanageswaran N, Demond M, Nagel M, Schreiner BS, Baumgart S, Scholz P, et al. Deep sequencing of the murine olfactory receptor neuron transcriptome. PloS One. 2015; 10 (1): e0113170.

137. Audrit KJ, Delventhal L, Aydin Ö, Nassenstein C. The nervous system of airways and its remodeling in inflammatory lung diseases. Cell Tissue Res. 2017; 367 (3): 571-90.

138. Wang T, Hu M, Chen X, Fu Y, Lei C, Dong H, et al. Caution on kidney dysfunctions of 2019-nCoV patients. MedRxiv. 2020.

139. Mubarak M, Nasri H. COVID-19 nephropathy; an emerging condition caused by novel coronavirus infection. J Nephropathol. 2020; 9 (3): e21.

140. Xu S, Fu L, Fei J, Xiang H-X, Xiang Y, Tan Z-X, et al. Acute kidney injury at early stage as a negative prognostic indicator of patients with COVID-19: a hospital-based retrospective analysis. medRxiv. 2020.

141. Zhang W, Zhao Y, Zhang F, Wang Q, Li T, Liu Z, et al. The use of anti-inflammatory drugs in the treatment of people with severe coronavirus disease 2019 (COVID-19): The experience of clinical immunologists from China. Clin Immunol. 2020: 214: 108393.

142. Peterson BK, Weber JN, Kay EH, Fisher HS, Hoekstra HE. Double digest RADseq: an inexpensive method for de novo SNP discovery and genotyping in model and non-model species. PloS One. 2012; 7 (5): e37135.

143. Diao B, Feng Z, Wang C, Wang H, Liu L, Wang C, et al. Human kidney is a target for novel severe acute respiratory syndrome coronavirus 2 (SARS-CoV-2) infection. Nat Commun. 2020; 12 (1): 2506.

144. Kuo Y-L, Jou I-M, Jeng S-F, Chu C-H, Huang J-S, Hsu T-I, et al. Hypoxia-induced epithelial-mesenchymal transition and fibrosis for the development of breast capsular contracture. Sci Rep. 2019; 9 (1): 1-6.

145. Tucker PS, Scanlan AT, Dalbo VJ. Chronic kidney disease influences multiple systems: describing the relationship between oxidative stress, inflammation, kidney damage, and concomitant disease. Oxid Med Cell Longev. 2015; 2015: 806358.

146. Li W, Moore MJ, Vasilieva N, Sui J, Wong SK, Berne MA, et al. Angiotensin-converting enzyme 2 is a functional receptor for the SARS coronavirus. Nature. 2003; 426 (6965): 450-4.

147. Hamming I, Timens W, Bulthuis M, Lely A, Navis Gv, van Goor H. Tissue distribution of ACE2 protein, the functional receptor for SARS coronavirus. A first step in understanding SARS pathogenesis. J Pathol. 2004; 203 (2): 631-7.

148. Galván Casas C, Catala A, Carretero Hernández G, Rodríguez-Jiménez P, Fernández-Nieto D, Rodríguez-Villa Lario A, et al. Classification of the cutaneous manifestations of COVID-19: a rapid prospective nationwide consensus study in Spain with 375 cases. Br J Dermatol. 2020; 183 (1): 71-7.

149. Ahmadian E, Hosseiniyan Khatibi SM, Razi Soofiyani S, Abediazar S, Shoja MM, Ardalan M, et al. Covid-19 and kidney injury: Pathophysiology and molecular mechanisms. Rev Med Virol. 2021; 31 (3): e2176.

150. Rubio-Muniz C, Puerta-Peña M, Falkenhain-López D, Arroyo-Andrés J, Agud-Dios M, Rodriguez-Peralto J, et al. The broad spectrum of dermatological manifestations in COVID-19: clinical and histopathological features learned from a series of 34 cases. J Eur Acad Dermatol Venereol. 2020; 34 (10): e574-6.

151. Reymundo A, Fernáldez-Bernáldez A, Reolid A, Butrón B, Fernández-Rico P, Muñoz-Hernández P, et al. Clinical and histological characterization of late appearance maculopapular eruptions in association with the coronavirus disease 2019. A case series of seven patients. J Eur Acad Dermatol Venereol. 2020; 34 (12): e755-7.

152. Askin O, Altunkalem RN, Altinisik DD, Uzuncakmak TK, Tursen U, Kutlubay Z. Cutaneous manifestations in hospitalized patients diagnosed as COVID-19. Dermatol Ther. 2020; 33 (6): e13896.

153. Gianotti R, Recalcati S, Fantini F, Riva C, Milani M, Dainese E, et al. Histopathological study of a broad spectrum of skin dermatoses in patients affected or highly suspected of infection by COVID-19 in the northern part of Italy: analysis of the many faces of the viral-induced skin diseases in previous and new reported cases. Am J Dermatopathol. 2020; 42 (8): 564-70.

154. Diotallevi F, Campanati A, Bianchelli T, Bobyr I, Luchetti MM, Marconi B, et al. Skin involvement in SARS-CoV-2 infection: case series. J Med Virol. 2020; 92 (11): 2332-4.

155. Radonjic-Hoesli S, Hofmeier KS, Micaletto S, Schmid-Grendelmeier P, Bircher A, Simon D. Urticaria and angioedema: an update on classification and pathogenesis. Clin Rev Allergy Immunol. 2018; 54 (1): 88-101.

156. Criado PR, Abdalla BMZ, de Assis IC, van Blarcum de Graaff Mello C, Caputo GC, Vieira IC. Are the cutaneous manifestations during or due to SARS-CoV-2 infection/COVID-19 frequent or not? Revision of possible pathophysiologic mechanisms. J Inflamm Res. 2020; 69 (8): 745-56.

157. Cappel JA, Wetter DA. Clinical characteristics, etiologic associations, laboratory findings, treatment, and proposal of diagnostic criteria of pernio (chilblains) in a series of 104

[Downloaded from jommid.pasteur.ac.ir on 2026-01-29]

[DOI: 10.52547/JoMMID.11.1.1]

patients at Mayo Clinic, 2000 to 2011. Mayo Clin Proc. 2014; 89 (2): 207-15.

158. Fernandez-Nieto D, Ortega-Quijano D, Jimenez-Cauhe J, Burgos-Blasco P, de Perosanz-Lobo D, Suarez-Valle A, et al. Clinical and histological characterization of vesicular COVID-19 rashes: a prospective study in a tertiary care hospital. Clin Exp Dermatol. 2020; 45 (7): 872-5.

159. Hughes M, Herrick AL. Raynaud's phenomenon. Best Pract Res Clin Rheumatol. 2016; 30 (1): 112-32.

160. Drago F, Ciccarese G, Gasparini G, Cogorno L, Javor S, Toniolo A, et al. Contemporary infectious exanthems: an update. Future Microbiol. 2017; 12 (2): 171-93.

161. Caputo V, Schroeder J, Rongioletti F. A generalized purpuric eruption with histopathologic features of leucocytoclastic vasculitis in a patient severely ill with COVID-19. J Eur Acad Dermatol Venereol. 2020; 34 (10): e579-81.

162. Magro C, Mulvey JJ, Berlin D, Nuovo G, Salvatore S, Harp J, et al. Complement associated microvascular injury and thrombosis in the pathogenesis of severe COVID-19 infection: a report of five cases. Transl Res. 2020; 220: 1-13.

163. Sajjan VV, Lunge S, Swamy MB, Pandit AM. Livedo reticularis: a review of the literature. Indian Dermatol Online J. 2015; 6 (5): 315-21.

164. Tang N, Li D, Wang X, Sun Z. Abnormal coagulation parameters are associated with poor prognosis in patients with novel coronavirus pneumonia. J Thromb Haemost. 2020; 18 (4): 844-7.

165. Manalo IF, Smith MK, Cheeley J, Jacobs R. Reply: A Dermatologic Manifestation of COVID-19: Transient Livedo Reticularis. J Am Acad Dermatol. 2020; 83 (2): e157.

166. Wheatland R. Molecular mimicry of ACTH in SARS–implications for corticosteroid treatment and prophylaxis. Med Hypotheses. 2004; 63 (5): 855-62.

167. Ding Y, He L, Zhang Q, Huang Z, Che X, Hou J, et al. Organ distribution of severe acute respiratory syndrome (SARS) associated coronavirus (SARS-CoV) in SARS patients: implications for pathogenesis and virus transmission pathways. J Pathol. 2004; 203 (2): 622-30.

168. Leow MKS, Kwek DSK, Ng AWK, Ong KC, Kaw GJL, Lee LSU. Hypocortisolism in survivors of severe acute respiratory syndrome (SARS). Clin Endocrinol. 2005; 63 (2): 197-202.

169. Scaroni C, Armigliato M, Cannavò S. COVID-19 outbreak and steroids administration: are patients treated for Sars-Cov-2 at risk of adrenal insufficiency? J Endocrinol Investig. 2020; 43 (7): 1035-6.

170. Wei L, Sun S, Zhang J, Zhu H, Xu Y, Ma Q, et al. Endocrine cells of the adenohypophysis in severe acute respiratory syndrome (SARS). Biochem Cell Biol. 2010; 88 (4): 723-30.

171. Xu J, Zhao S, Teng T, Abdalla AE, Zhu W, Xie L, et al. Systematic comparison of two animal-to-human transmitted human coronaviruses: SARS-CoV-2 and SARS-CoV. Viruses. 2020; 12 (2): 244.

172. Reis FM, Bouissou DR, Pereira VM, Camargos AF, dos Reis AM, Santos RA. Angiotensin-(1-7), its receptor Mas, and the angiotensin-converting enzyme type 2 are expressed in the human ovary. Fertil Steril. 2011; 95 (1): 176-81.

173. Verma S, Saksena S, Sadri-Ardekani H. ACE2 receptor expression in testes: implications in coronavirus disease 2019 pathogenesis. Biol Reprod. 2020; 103 (3): 449-51.

174. Bahadur G, Acharya S, Muneer A, Huirne J, Łukaszuk M, Doreski PA, et al. SARS-CoV-2: diagnostic and design conundrums in the context of male factor infertility. Reprod Biomed Online. 2020; 41 (3): 365-9.

175. Vaz-Silva J, Carneiro M, Ferreira M, Pinheiro S, Silva D, Silva A, et al. The vasoactive peptide angiotensin-(1–7), its receptor Mas and the angiotensin-converting enzyme type 2 are expressed in the human endometrium. Reprod Sci. 2009; 16 (3): 247-56.

176. Xu J, Qi L, Chi X, Yang J, Wei X, Gong E, et al. Orchitis: a complication of severe acute respiratory syndrome (SARS). Biol Reprod. 2006; 74 (2): 410-6.

177. Pan F, Xiao X, Guo J, Song Y, Li H, Patel DP, et al. No evidence of severe acute respiratory syndrome–coronavirus 2 in semen of males recovering from coronavirus disease 2019. Fertil Steril. 2020; 113 (6): 1135-9.

178. Gagliardi L, Bertacca C, Centenari C, Merusi I, Parolo E, Ragazzo V, et al. Orchiepididymitis in a boy with COVID-19. Pediatr Infect Dis. 2020; 39 (8): e200-2.

179. Illiano E, Trama F, Costantini E. Could COVID-19 have an impact on male fertility? Andrologia. 2020; 52 (6): e13654.

180. Ma L, Xie W, Li D, Shi L, Mao Y, Xiong Y, et al. Effect of SARS-CoV-2 infection upon male gonadal function: A single center-based study. MedRxiv. 2020.

181. Kusmartseva I, Wu W, Syed F, Van Der Heide V, Jorgensen M, Joseph P, et al. ACE2 and SARS-CoV-2 Expression in the Normal and COVID-19 Pancreas. bioRxiv. 2020.

182. Li D, Jin M, Bao P, Zhao W, Zhang S. Clinical characteristics and results of semen tests among men with coronavirus disease 2019. JAMA Netw Open. 2020; 3 (5): e208292.

183. Dube GK, Husain SA, McCune KR, Sandoval PR, Ratner LE, Cohen DJ. COVID-19 in pancreas transplant recipients. Transpl Infect Dis. 2020: 22 (6): e13359.

184. Musa SS, Zhao S, Wang MH, Habib AG, Mustapha UT, He D. Estimation of exponential growth rate and basic reproduction number of the coronavirus disease 2019 (COVID-19) in Africa. Infect Dis Poverty. 2020; 9 (1): 96.

Cite this article:
Ahmadzadeh S, Sedighi M, Torkashvand A, Hashemzadeh P, Shafiei F, Tokashvand M, Hasan-Zadeh A. Pathological Effects of COVID-19 on Body Organs. J Med Microbiol Infect Dis, 2023; 11 (1): 1-19. DOI: 10.52547/JoMMID.11.1.1

[Downloaded from jommid.pasteur.ac.ir on 2026-01-29]

[DOI: 10.52547/JoMMID.11.1.1]