

Ophidascaris sp. in an African Rock Python (*Python sebae*) in Ghana: A Case Report

Langbong Bimi^{1*}, Freda Kailyn Odamtten¹, Francis Anto², Ato Kwamena Tetteh³

¹Department of Animal Biology and Conservation Science, University of Ghana, Legon, Accra, Ghana; ²School of Public Health, University of Ghana, Legon, Accra, Ghana; ³School of Public Health, Georgia State University, Atlanta, Georgia, United States

ARTICLE INFO

Case Report

Keywords: Python, *Ophidascaris*, Ghana

Received: 25 May, 2021

Received in revised form: 22 Jul, 2021

Accepted: 26 Jul, 2021

DOI: 10.52547/JoMMID.9.2.103

*Correspondence

Email: lbimi@ug.edu.gh

Tel: +23324 3521393

Fax:

© The Author(s)



ABSTRACT

This study reports an *Ophidascaris* sp. infection in the gastrointestinal tract of a python snake found at a construction site in Labone, a suburb of Accra and the capital city of Ghana. Examination of the rectal contents of the snake by the zinc sulfate centrifugal floatation method revealed helminths eggs. Besides, examining various sections of the alimentary canal revealed adult worms of the genus *Ophidascaris* in the anterior half of the small intestine just below the stomach's pyloric sphincter. Also, milking one of the female worms onto a microscope slide and examining the exudate by microscopy following staining with Lugol's iodine dye revealed eggs. Our findings may alert the possibility of zoonotic transmission of the parasite from pythons to humans, especially in the suburban/rural areas where people consume snake meat.

INTRODUCTION

The African rock python, *Python sebae* (Gmelin, 1789), is Africa's largest snake and one of the six most giant species worldwide [1]. This non-venomous snake, widely distributed in sub-Saharan Africa and measures up to 7.5 m in length in its natural habitat [2]. They are adapted to forests, grasslands, and human-modified landscapes but commonly live near water bodies [3, 4]. Thus, living mainly in these terrains and aquatic ecosystems may expose these snakes to infections by the eggs or larvae of parasitic helminths.

It is also pertinent to note that the origin of many neglected tropical diseases, mainly bacteria and viruses, is wildlife species. Human activities have increased contact with game animals, and these animals may serve either as the intermediate, reservoir, or accidental host in the sylvatic cycle. The epidemiological data on zoonotic wildlife parasites is scanty due to poor surveillance strategies in Africa; therefore, studies are necessary to develop preventive and control measures [5].

Like other reptiles, pythons are intermediate, paratenic, or definitive hosts of a series of endoparasites [6]. In Africa, the giant snake *python sebae* acquire

helminths infection through preying on amphibians and small mammals, the intermediate hosts, or carriers of helminths [3]. Nematodes of the Ascarididae family, *Ophidascaris* sp., are principally found in pythonid and colubrid snakes and may often cause gastrointestinal, hepatic, and pulmonary lesions [6]. According to some studies, ascarids live in the gastrointestinal tract of snakes, in inflammatory nodules near the gastric pylorus, distal esophagus, stomach, and small intestine [7].

As snakes pathogens, ascarid nematode infection can be fatal [8]. Unfortunately, there are very few reports of *Ophidascaris filaria* in the African rock python [9]. Thus, new records from different localities might shed more light on the distribution of this nematode.

CASE REPORT

A snake was captured at a construction site at Labone (5.5683° N, 0.1717° W), a suburb of Accra, and the capital city of Ghana (Fig. 1). This suburb, a low-lying marshy area covered with bushes, is ~ 8 km away from the beach.

The snake, an African rock python (Fig. 2), was killed by workers at the construction site and was sent to the

Department of Animal Biology and Conservation Science.

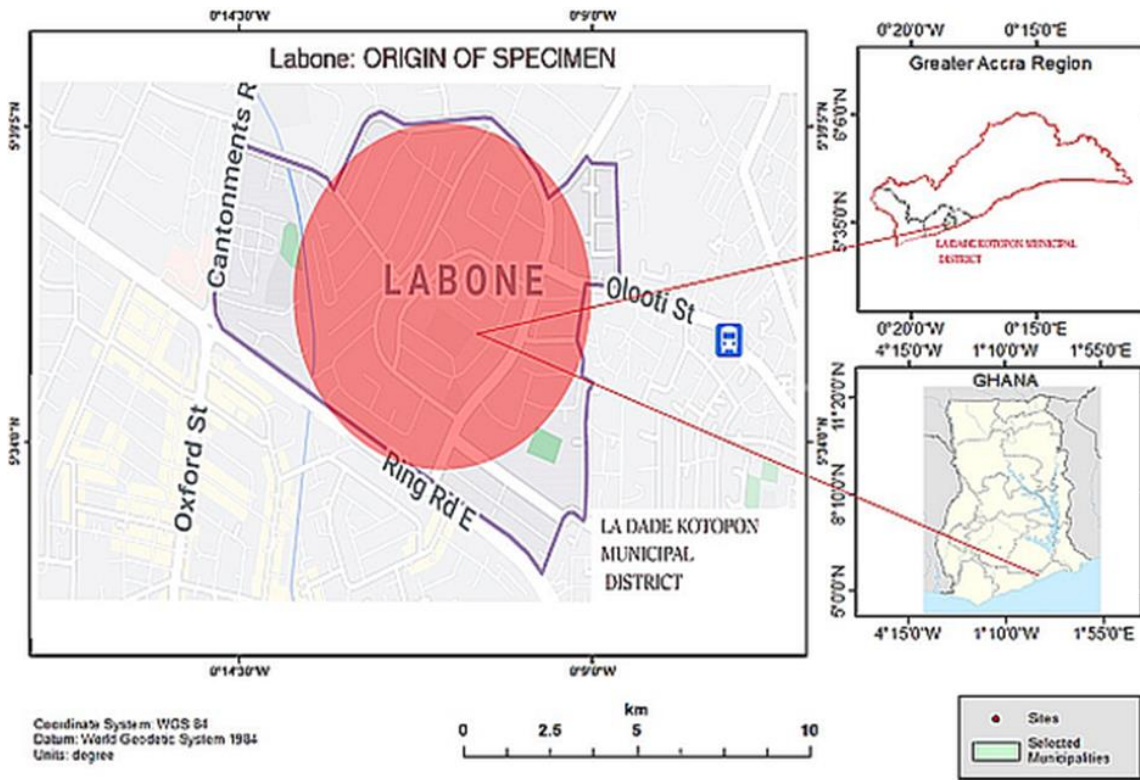


Fig. 1. Map of Ghana showing the area of Accra where the snake was captured.



Fig. 2. African Rock Python (*Python sebae*)

The snake weighed 33.6 kg and was 3.2 m long. Other morphometric measurements included midsection circumference (33.0 cm), head circumference (15.0 cm), head length (mouth to the neck, 11.0 cm), and tail length (31.0 cm). The whole length of the gastrointestinal tract measured 156 cm, and the liver, spleen, and trachea were 57 cm, 48 cm, and 77 cm, respectively. To investigate

the snake's gastrointestinal parasites, ~2 g of feces was taken from the rectum by forceps and processed by the zinc sulfate centrifugal floatation method [10]. The top layer in the test tubes was pipetted onto microscope slides and examined under a compound microscope with 10× magnification, which revealed some helminth eggs (Fig. 3A).

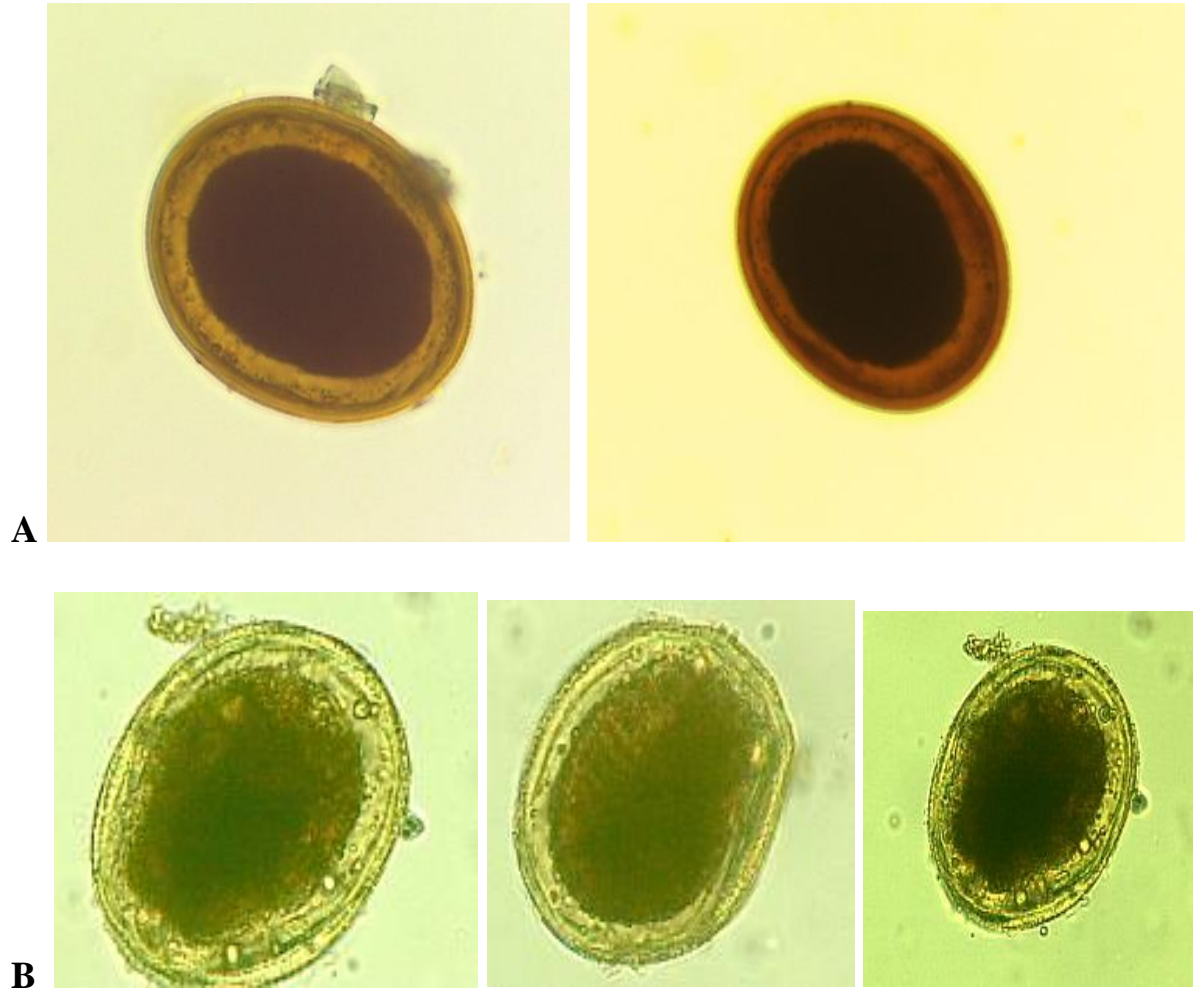


Fig. 3. *Ophidascaris sp* eggs isolated from Rectal content (A) and exudate of milked worm (B)

A longitudinal incision was made along the snake's ventral section to open the body cavity from the throat to the vent. The gut contents were examined thoroughly with a magnifying glass for adult parasites. Various sections of the alimentary canal were cut off and opened, and the contents were washed with 0.9% saline in a 250-ml volume cylindrical bowls and examined thoroughly with a hand lens (10x magnification) for adult worms. Nine adult helminths (Fig. 4) were found in the anterior half of the small intestine just below the stomach's pyloric sphincter. The worms were preserved in 70% ethanol and later identified according to previous descriptions [11].

The worms were cream-colored and showed no trace of ingested blood (Fig. 4). Examination of adult worms under a compound light microscope at 40x as described by others [12] revealed three lips armed with papillae at the anterior ends of the adult worms, as seen in the ascaridoids [13]. The three relatively smaller males measured 63 mm, 82 mm, and 117 mm in length. Likewise, the body length of the female worms ranged from 88 mm to 142 mm. These morphologic and morphometric characteristics of the specimens matched that of *Ophidascaris sp.* [13].

Also, one of the female worms was 'milked onto' a microscope slide, and the exudate was examined under a microscope at 10x magnification after staining with Lugol's iodine dye. Interestingly, some eggs were

observed in this milked exudate (Fig. 2B). The presence of mature eggs in the adult worms might imply that much of the female nematodes were filled with eggs at maturity.

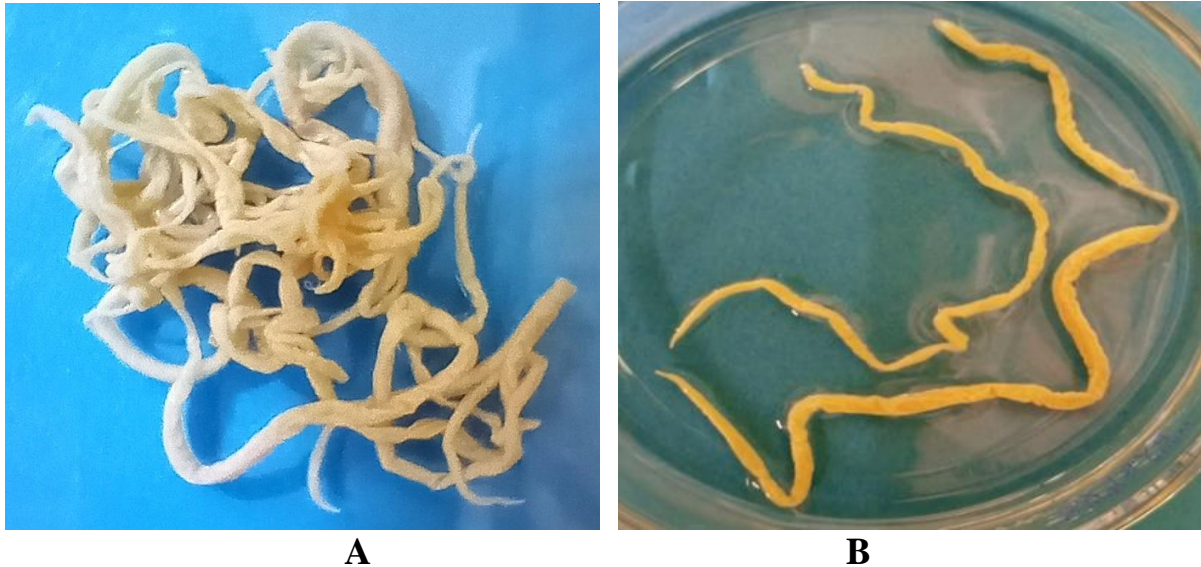


Fig. 4. Adult *Ophidascaris* sp. isolated from the small intestine of *Python sebae*. Entangled worms (A) and separated worms (B)

DISCUSSION

Among various worms reported to infect snakes are ascaroid nematodes, including *Ophidascaris* spp, with a special report of *Ophidascaris filaria* found in a dead python from Iran [8, 14]. This gastrointestinal nematode is found in snakes worldwide [18], infecting various species [6, 13]. These nematodes are often embedded in inflammatory nodules near the gastric pylorus, distal esophagus, stomach, or small intestine [7].

It is noteworthy that, as the proportion of snakes in bush meat gradually increases, infections with zoonoses like pentastomiasis are emerging as a concern [14]. Although these emerging spillover infections with novel and exotic pathogens to the human host [15] are becoming a threat, they are commonly under-researched [16]. The few reports of human cases of pentastomiasis infections in Ghana were associated with the socio-cultural practices of clans that keep pythons in their homes as their totem, giving room for transmission of the parasite to humans [17]. The python we examined might have acquired the infestation by preying on infected rodents or other small mammals.

Our report is the first record of *Ophidascaris* sp. infection in a python in Ghana or even the West African sub-region. Thus, our findings might raise concerns about the possibility of zoonotic transmission of the parasites from snakes to humans, especially in the suburban/rural areas where people consume snake meat [18].

ACKNOWLEDGMENT

The authors are very grateful to the Department of Animal Biology and Conservation Science technicians for their help in performing the parasitological examinations. This investigation did not receive any form of funding.

CONFLICT OF INTEREST

The authors declare that there are no conflicts of interest associated with this manuscript.

REFERENCES

1. Branch W, Hacke W. A fatal attack on a young boy by an African rock python, *Python sebae*. *J Herpetol.* 1980; 14 (3): 305-7.
2. Starin E, Burghardt G. African rock pythons (*Python sebae*) in the Gambia: observations on natural history and interactions with primates. *Snake.* 1992; 24 (1): 50-62.
3. Luiselli L, Angelici FM, Akani GC. Food habits of *Python sebae* in suburban and natural habitats. *Afr J of Ecol.* 2001; 39 (1): 116-8.
4. Murphy JC, Henderson RW. Tales of giant snakes: a historical natural history of anacondas and pythons: Krieger Publishing Company USA; 1997.

5. Odeniran PO, Ademola IO. Zoonotic parasites of wildlife in Africa: A review. *Afr J Wildl Res.* 2016; 46 (1): 1-13.
6. Murvanidze L, Lomidze T, Nikolaishvili K. The Endoparasites (Pentastomida, Nematoda) of African Rock Python (*Python sebae* Gmelin, 1788) in Tbilisi Zoological Park. *Bull Georgian Natl Acad Sci.* 2015; 9 (3): 143-9.
7. Sundar SB, Kavitha KT, Gomathinayagam S, Sangaran A, Latha BR, Harikrishnan, TJ. A report on the incidence of *Ophidascaris sp.* in a reticulated python. *Int J Environ Sci Technol.* 2016; 5 (5): 3328-31.
8. Ganjali M, Keighobadi M, Khedri J. First report of *Ophidascaris filaria* (Nematode: Ascarididae) from the Indian python in Sistan, Iran. *Comp Clin Path.* 2015; 24 (5): 1285-8.
9. Elbihari S, Hussein M. *Ophidascaris filaria* (Dujardin 1845) from the African rock python, *Python sebae*, in the Sudan, with a note on associated gastric lesions. *J Wildl Dis.* 1973; 9 (2): 171-3.
10. Parameshwarappa K, Chandrakanth C, Sunil B. The Prevalence of Intestinal Parasitic Infestations and the Evaluation of Different Concentration Techniques of the Stool Examination. *J Clin Diagn Res.* 2012; 6 (7): 1188-91.
11. Sprent J. Studies on ascaridoid nematodes in pythons: speciation of *Ophidascaris* in the Oriental and Australian regions. *Parasitology.* 1969; 59 (4): 937-59.
12. Soota TD, Chaturvedi Y. On five new species of nematodes from vertebrates. *P Natl A Sci India B.* 1970; 71 (3): 100-8.
13. Suwanti LT, Audini IS, Koesdarto S, Poetranto ED. Morphologic and morphometric characteristics of ascaroid worm, *Ophidascaris piscatori* in *Xenochrophis piscator* snake in Sidoarjo, Indonesia. *Vet World.* 2018; 11 (8): 1159-63.
14. Karesh WB, Noble E. The bushmeat trade: increased opportunities for transmission of zoonotic disease. *Mt Sinai J Med.* 2009; 76 (5): 429-34.
15. Sulyok M, Rózsa L, Bodó I, Tappe D, Hardi R. Ocular pentastomiasis in the Democratic Republic of the Congo. *PLoS Negl Trop Dis.* 2014; 8 (7): e3041.
16. Dakubo J, Naaeder S, Kumodji R. Totemism and the transmission of human pentastomiasis. *Ghana Med J.* 2008; 42 (4): 165-8.
17. Ayinmode, A., Adedokun, A., Aina, A, Taiwo, V. The zoonotic implications of pentastomiasis in the royal python (*Python regius*). *Ghana Med J.* 2010; 44 (3): 115-8.
18. Patra G, Jamoh K, Ghosh S, Saikia B, Lalnunpuia C, Debbarma A, et al. Recovery of *Ophidascaris sp.* and *Polydelphis sp.* from the Indian python in Aizawl district of Mizoram, India. *Int J Appl Microbiol Biotechnol Res.* 2018; 6 (1): 1-7.

Cite this article:

Bimi L, Odamtten FK, Anto F, Tetteh AK. *Ophidascaris sp. in an African Rock Python (Python sebae) in Ghana: A Case Report.* *J Med Microbiol Infect Dis*, 2021; 9 (2): 103-107. DOI: 10.52547/JoMMID.9.2.103.