

Helminth Parasites of Bats (Chiroptera: Rhinopomatidae Bonaparte, 1838) from the Persian Gulf Coastal Area

Elham Kazemirad¹ , Alireza Latifi¹ , Iraj Mobedi¹ , Vahid Akmal² , Hamed Mirjalali³ , Gholamreza Mowlavi^{1*} 

¹ Department of Medical Parasitology and Mycology, School of Public Health, Tehran University of Medical Sciences, Tehran, Iran; ²Department of Biology, Faculty of Science, Razi University, Kermanshah, Iran; ³Foodborne and Waterborne Diseases Research Center, Research Institute for Gastroenterology and Liver Diseases, Shahid Beheshti University of Medical Sciences, Tehran, Iran

ARTICLE INFO

Original Article

Keywords: Chiroptera, *Rhinopoma* bats, Gastrointestinal helminths, Iran

Received: 26 Sep. 2020

Received in revised form: 09 Nov. 2020

Accepted: 25 Nov. 2020

DOI: 10.29252/JoMMID.8.3.118

*Correspondence

Email: molaviva@tums.ac.ir

Tel: +982188951392

Fax: +982188951392

ABSTRACT

Introduction: Bats are natural reservoir hosts of several zoonotic infections. Few studies have demonstrated gut helminth community parasite in bats. In the present study, we investigated two intestinal helminths of two bat species, *Rhinopoma muscatellum*, and *Rhinopoma microphyllum*, from Hormozgan province, southern Iran. **Methods:** We received digestive tracts of 56 *Rhinopoma* bats previously captured by several biologists. The specimens were precisely dissected and examined for the parasitic helminths. The collected helminths were cleared in the lactophenol and identified using reliable morphological and morphometrical key references. **Result:** In this study, 44 *R. muscatellum* and 6 *R. microphyllum* species were examined, among which 15 (26.7%) had infections with parasitic worms. *Lecithodendrium* sp. and *Castoria* sp. were identified in the digestive tract of eight and four individually examined *R. muscatellum* bats, respectively. Also, in three *R. microphyllum* bats, a few spirurid nematodes with incomplete structures were detected. **Conclusion:** We, for the first time, identified *Lecithodendrium* sp., *Castoria* sp., in *R. muscatellum* from south of Iran. Due to the insectivorous biological trait of bats, the most abundant helminth was *Lecithodendrium* sp. Further study with more samples is needed to describe the helminths fauna of microbats in Iran taxonomically.

INTRODUCTION

Mouse-tailed bats are a group of insectivorous microbats of the family Rhinopomatidae, with only three to six species in the single genus of *Rhinopoma* according to different reliable references [1-3]. They are prevalent in the Old World, from North Africa to Thailand and Sumatra, in arid and semiarid regions, roosting in caves, houses, and even the Egyptian pyramids. These microbats are moderately small, with a 5-6 Cm body and a weight ranging from 6-14 g [1, 2]. In Iran, the most prevalent *Rhinopoma* species is the small mouse-tailed bat (*R. muscatellum*). This bat has a free tail, which in most cases, is longer than the forearm length. This species has a hairless face with a small noseleaf on the snout and large ears connected across the forehead [3]. *R. muscatellum* has a limited distribution around the Persian Gulf and occurs in Oman, Yemen, the United Arab Emirates, Afghanistan, Western Pakistan, and India and Iran's coastal area [4, 5]. The other

Rhinopoma species, *R. microphyllum*, a greater mouse-tailed bat, prevails in southwestern Iran. In this species, the skull length is 18-22 mm, and the forearm measures 57-72 mm. The *Rhinopoma* species live in colonies in caves, holes, and quiet houses and feed on insects and hunts using echolocation [2, 5].

There is substantial evidence that bats serve reservoirs for various zoonotic pathogens, including viruses, fungi, parasites, and bacteria. Hence, contact between bats, other animals, and humans can cause interspecies transmissions and disease outbreaks [6]. Bats harbor zoonotic viruses such as SARS COVID-19, SARS coronavirus, Nipah virus, Hendra virus, and Ebola virus [7, 8]. These small mammals carry protozoans of the genera *Plasmodium* and *Trypanosoma* and parasitic helminths, including trematodes, cestodes, and nematodes [9]. Moreover, ectoparasites like ticks, mites,

bugs (Hemiptera), fleas (Siphonaptera), and flies (Diptera) parasitize these small mammals [10].

Several studies have investigated the microbial community inhabiting bats regarding bats' impact as reservoirs of emerging infectious diseases [6-8]. However, few studies have focused on the parasite diversity within bats. For the first time in this study, we investigated the gastrointestinal tract of *R. muscatellum* and *R. microphyllum* from the south of Iran for parasitic helminths.

MATERIALS AND METHODS

In the present study, 56 digestive tracts of bat carcasses previously captured and identified by zoologists were transferred to the Helminthology

Laboratory at Tehran University of Medical Sciences. The bats had been captured in the Hormozgan province of Iran, the Persian Gulf northern littoral areas (Fig1), and the specimens were preserved at -20 °C. The gastrointestinal tracts were cut open longitudinally, and the entire contents were transferred to normal saline and carefully examined for helminths under a stereomicroscope and in higher magnifications (100X and 400X) by a microscope. The collected worms were cleared in lactophenol to become transparent, stained with azocarmine and carmine acid, and then were mounted using Canada balsam. The identification of Helminths was achieved based on morphological and morphometrical characters using reliable key references [12, 13].

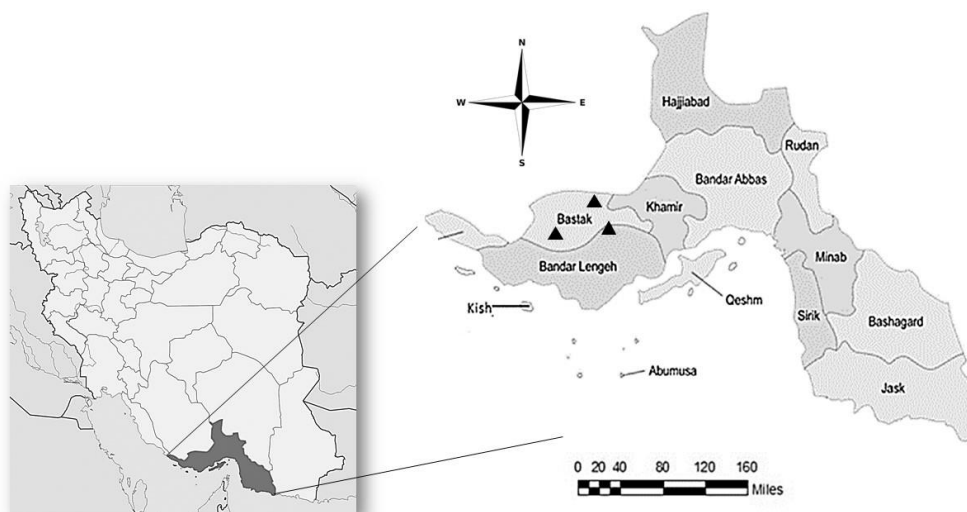


Fig 1. Map of Iran and the sampling area (Hormozgan province, the Persian Gulf northern littoral areas); triangles illustrate the sampling localities.

RESULTS

In this study, the intestinal content of 50 *R. muscatellum* and 6 *R. microphyllum* bats were examined for helminths. Out of 56 bats, 15 (26.78%) had infections with parasitic worms, and 41 (73.21%) showed no helminth infection. *Lecithodendrium* sp. and *Castoria* sp. were observed in the digestive tract of eight and four individually examined *R. muscatellum* bats, respectively (Figs 2, 3, and Table1). In three *R. microphyllum* bats, some damaged spirurid nematodes, most probably of the

genus *Physaloptera*, were also detected. Overall, *Lecithodendrium* sp. was the most abundant helminths in the gastrointestinal tracts of *R. muscatellum* (Table1). No helminths mixed infection was observed in bats.

Morphological characters. The recovered trematode specimens from the *R. muscatellum* bats were measured carefully, as described below, and compared with specimens described in Russian references [13].

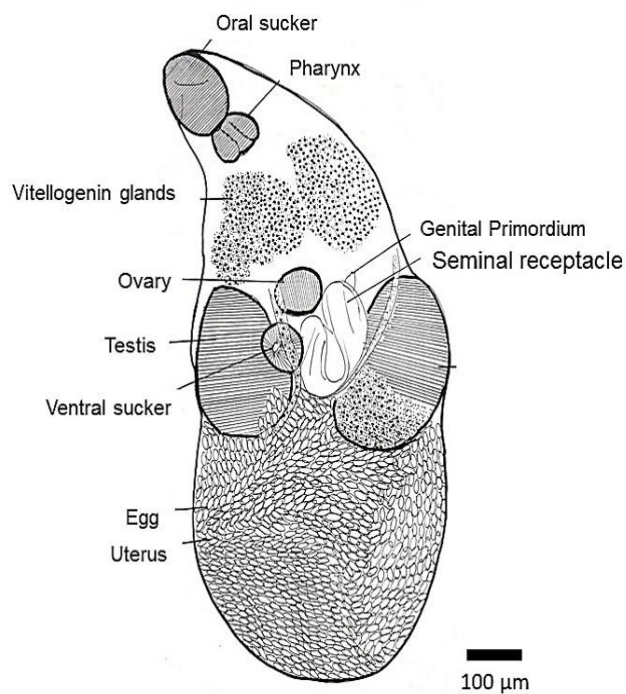


Fig 2. *Lecithodendrium* sp. isolated from *R. muscatellum* bats, drawn by camera lucida (10X).

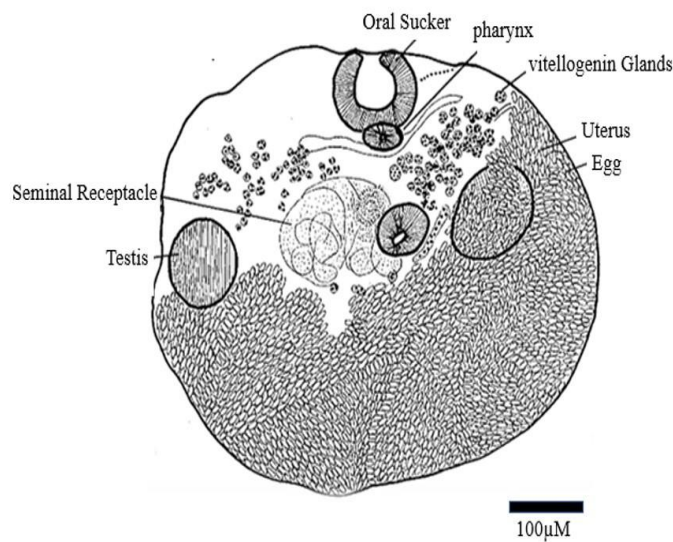


Fig 3. *Castoria* sp. isolated from *R. muscatellum* bats, drawn by camera lucida (10X).

Table1. Different species of helminth parasites in the *Rhinophyma* bat.

Helminths species	Bat species		Total No. (%)
	<i>R. muscatellum</i> (No.)	<i>R. microphyllum</i> (No.)	
<i>Lecithodendrium</i> sp.	8	-	8 (14.28%)
<i>Castoria</i> sp.	4	-	4 (7.14%)
Spirurid nematodes, <i>Physaloptera</i> sp.	-	3	3 (5.35%)
uninfected	38	3	41 (73.21%)
Total	50	6	56

***Lecithodendrium* sp.** The parasites measured ~1.04 mm in length and ~0.44 in width in the middle of the worm oral sucker 140 to 100 μm above the small pharynx 80 to 60 μm. Two lobbed elongate testis at the middle part of the body about 160-170 and 250-300 μm, located bilaterally. The ovary 70-80 μm was above the margin of the 60-80 μm ventral sucker. The distance between the oral sucker and ventral sucker was 450 μm. The uterus, filled with the eggs, has occupied almost half of the body length (Fig 2).

***Castoria* sp.** The specimens were ~0.52 mm long and ~0.60 mm in width, with two small smooth indentations on either side of the oral sucker and a small depression in the middle of the posterior end into which the excretory system opens. The oral sucker was ~100 μm closed with a small pharynx and a ~50 μm ventral sucker. Testes were elongated in the transverse direction with a seminal receptacle, dotted vitelline, and convoluted uterus filled with eggs about ~10 μm in length (Fig 3).

DISCUSSION

Bats are the natural reservoirs for various zoonotic diseases. Several studies have demonstrated the microbial infection in bats; however, the information on the helminth that parasites are scarce [1]. The present study investigated the helminths parasites of the bats belonging to the *Rhinopoma* genus from the south of Iran. Out of 50 *R. muscatellum* bats, 15 (26.7%) showed helminth infections in the gastrointestinal tract; eight had infections with the trematode *Lecithodendrium* sp., four with *Castoria* sp., the first *R. muscatellum* infection report with these helminths in Iran.

Studies that focus on bat endoparasites are rarely available in the literature. In Iran, the only work on 18 lesser mouse-eared bats, *Myotis blythii* (Chiroptera, Vespertilionidae) from Zanjan Province, revealed *Hymenolepis rhinopomae*, *Molinostrongylus alatus* in the digestive tract of these bats. *M. blythii* was defined as the new host for *H. rhinopomae*, and *M. alatus* in this bat species was reported for the first time in Iran [14].

In a similar survey on pipistrelle bats (*Pipistrellus pipistrellus* and *P. pygmaeus*) in the Greater Manchester and Lancashire region of England, of 90 adult and juvenile bats examined for gastrointestinal helminths by

morphological and molecular analyses, 68 (76%) had infections with at least one species of digenean trematodes including *Lecithodendrium linstowi*, *L. spathulatum*, *Prosthodendrium* sp., *Plagiorchis koreanus*, and *Pycnporus heteroporus* [15].

A study in Egypt on 1264 bats from eight different species, including *Rousettus aegyptiacus*, *R. hardwickei*, *R. microphyllum*, *Taphozous nudiventris*, *Nycteris thebaica*, *Rhinolophus clivosus*, *Otonycteris hemprichii*, and *Asellia tridens*, demonstrated that the strict host specificity was not a notable feature of trematode infections. However, a definite preference for some trematodes genera to certain bat species was observed [16].

In China, 56 bats from eight species belonging to the families Rhinolophidae, Hipposideridae, Vespertilionidae, and Molossidae were investigated for parasitic helminths. Infections with cestodes of *Vampirolepis* sp. were detected in Rhinolophidae bats, and *Hymenolepis* sp. was identified in Hipposideridae bats [17].

Roskopf *et al.* (2019) detected *Nycteria* (order Haemosporida), an arthropod-borne blood parasite in *Rhinolophus* bats, and *Polychromophilus* in *Miniopterus minor* bats in Ngounié province, Gabon [18]. In Serbia, an examination of 118 bats revealed six digenean species, including *Lecithodendrium linstowi*, *Plagiorchis* sp., *Prosthodendrium longiforme*, *P. chilostomum*, *P. parvouterus*, and *Mesotretes peregrinus* [19].

Similar to previous reports, in our study, due to the host's diet, the most prevalent helminths in *Rhinophoma* bats was a digenean trematode, *Lecithodendrium* sp., followed by *Castorai* sp. Indeed, metacercaria of digenean trematodes often develops in the body of larvae and nymphs of aquatic insects of the order Plecoptera, Ephemeroptera, Odonata, or Trichoptera [20]. Given that *Rhinopomatidae* bats are insectivorous, having these trematode infections is highly probable.

Moreover, in the current study, the spirurid parasite, *Physaloptera* sp. were also detected in *R. microphyllum*, while the partially damaged worms did not allow us to reach a conclusive identification of the species. Since this helminth's zoonotic aspect is a concern from the public health perspective, further studies are required to investigate bats' potential role in accidental human

infection. The current paper illustrated *Lecithodendrium* spp., *Castoria* spp., in *R. muscatellum* in the south of Iran for the first time. We hope that this study triggers further works to improve our knowledge of bats' possible role in the emergence of zoonotic agents.

ACKNOWLEDGMENT

The authors are grateful to acknowledge the Department of Zoology, Faculty of Sciences at Tehran University, for providing the samples.

CONFLICT OF INTEREST

The authors declare that there are no conflicts of interest associated with this manuscript.

REFERENCES

- Macdonald, D. The Encyclopedia of Mammals. New York: Facts on File. 1984. 800.
- Fenton, M. Brock. Bats. New York: Checkmark Books. 2001; 122-4.
- Kafaei S, Akmal V, Sharifi M. Using the Ensemble Modeling Approach to Predict the Potential Distribution of the Muscat Mouse-Tailed Bat, *Rhinopoma muscatellum* (Chiroptera: Rhinopomatidae), in Iran. Iranian J Sci and Technol Trans A Sci. 2020; 25 (1-2): 1337-48.
- Akmal V, Farazmand A, Darvish J, Sharifi M. Phylogeography and taxonomic status of the greater mouse-tailed bat *Rhinopoma microphyllum* (Chiroptera: Rhinopomatidae) in Iran. Acta Chiropt. 2011; 13 (2): 279-90.
- Kafaei S, Sharifi M, Akmal V. Population Genetic Structure and Phylogeography of the Small Mouse-Tailed Bat, *Rhinopoma muscatellum* Thomas, 1903 (Chiroptera: Rhinopomatidae) in Iran Inferred from Mitochondrial DNA. Acta Chiropt. 2020; 22 (1): 29-40.
- Allocati N, Petrucci AG, Di Giovanni P, Masulli M, Di Ilio C, De Laurenzi V. Bat-man disease transmission: zoonotic pathogens from wildlife reservoirs to human populations. Cell Death Discov. 2016; 2 (1): 1-8.
- Yan-Rong Guo, Qing-Dong Cao, Zhong-Si Hong, Yuan-Yang Tan, Shou-Deng Chen, Hong-Jun Jin, et al. The origin, transmission and clinical therapies on coronavirus disease 2019 (COVID-19) outbreak - an update on the status. Mil Med Res. 2020; 13;7 (1): 11.
- Wang LF, Anderson DE. Viruses in bats and potential spillover to animals and humans. Curr Opin Virol. 2019; 3 (4): 79-89.
- Angoma DM, Flores GM, De la Cruz JC, Chanchahuña CC, Iannaccone J. Helminth parasites of bats (Chiroptera, Phyllostomidae) in the Department of Junin, Peru and Check list of records made in Peru. Revista del Museo Argentino de Ciencias Naturales nueva serie. 2020; 22 (1): 57-73.
- Haelewaters D, Pfliegler WP, Szentiványi T, Földvári M, Sándor AD, Barti L, et al. Parasites of parasites of bats: Laboulbeniales (Fungi: Ascomycota) on bat flies (Diptera: Nycteribiidae) in central Europe. Parasit Vector. 2017; 10 (1): 96.
- DeBlase Anthony F. The bats of Iran: systematics, distribution, ecology. Fieldiana Zool, 1981. p. 861.
- Dietz C. Illustrated identification key to the bats of Egypt. Electronic publication, version. 2005 Dec 21; 1.
- Skrjabina E, S.: Helminths of sturgeons. Publishing house 'Nauka'. 1974. 1-168. Russian.
- Hemmati F, Rezazadeh E, Kiabi BH, Hemmati L, Molavi G, Radd EK, et al. Parasites of the Lesser Mouse-Eared Myotis, *Myotis blythii* (Chiroptera, Vespertilionidae), from Zanjan Province, Northwest Iran. Comp Biol. 2013; 80 (2): 312-3.
- Lord JS, Parker S, Parker F, Brooks DR. Gastrointestinal helminths of pipistrelle bats (*Pipistrellus pipistrellus*/*Pipistrellus pygmaeus*) (Chiroptera: Vespertilionidae) of England. Parasitology. 2012; 139 (3): 366-74.
- Ashour AA, Ahmed SE. Studies on the helminth parasites of birds from Egypt: 1-trematoda and cestoda. J Egypt Soc Parasitol. 1996; 26 (1): 207-16.
- Sawada I, Harada M, Wu Y. Cestode parasites of some bats from the People's Republic of China. Parasitol Int. 1998; 47 (2): 149-56.
- Roskopf SP, Held J, Gmeiner M, Mordmüller B, Matsiégui PB, Eckerle I, et al. Nycteria and Polychromophilus parasite infections of bats in Central Gabon. Infect Genet Evol. 2019; 68: 30-4.
- Horvat Ž, Čabrilo B, Paunović M, Karapandža B, Jovanović J, Budinski I, et al. Gastrointestinal digenaeans (Platyhelminthes: Trematoda) of horseshoe and vesper bats (Chiroptera: Rhinolophidae and Vespertilionidae) in Serbia. Helminthologia. 2017; 54 (1): 17-25.
- Hall JE. Some lecithodendriid metacercariae from Indiana and Michigan. J Parasitol. 1960; 46 (3): 309-14.

Cite this article:

Kazemirad E, Latifi A, Mobedi I, Akmal V, Mirjalili H, Mowlavi GH. Helminth parasites of bats (Chiroptera: Rhinopomatidae Bonaparte, 1838) from the Persian Gulf coastal area. J Med Microbiol Infect Dis, 2020; 8 (3): DOI: 10.29252/JoMMID.8.3.118