

## Nocardiosis: An Essential Diagnostic Challenge in Suspected Pulmonary Tuberculosis

Asem Ali Ashraf<sup>1</sup> , Pratibha Bhat U.<sup>1\*</sup> 

<sup>1</sup>Nitte (Deemed to be University), KS Hegde Medical Academy (KSHEMA), Department of Microbiology, Mangalore, Karnataka, India.

### ARTICLE INFO

#### Case Report

**Keywords:** *Nocardia* species, pulmonary nocardiosis, immunocompromised, diagnostic challenge, tuberculosis mimic, BAL fluid analysis, acid-fast staining, HIV-related infections

Received: 14 Apr. 2024

Received in revised form: 08 Nov. 2024

Accepted: 10 Nov. 2024

DOI: 10.61186/JoMMID.12.3.235

#### \*Correspondence

Email: pratibhabhat.u@gmail.com

Tel: +919482274526

© The Author(s)



### ABSTRACT

**Introduction:** Nocardiosis is a globally recognized opportunistic infection that predominantly affects immunocompromised individuals, leading to a diverse range of clinical manifestations, from cutaneous to severe systemic forms. The similarity of pulmonary nocardiosis symptoms to those of pulmonary tuberculosis often leads to misdiagnosis, presenting a significant diagnostic challenge for clinicians. We present an illustrative case of a 48-year-old male, newly diagnosed with HIV, who exhibited symptoms initially suggestive of pulmonary tuberculosis but was subsequently diagnosed with pulmonary nocardiosis. **Methods:** Bronchoalveolar lavage (BAL) fluid samples were obtained and subjected to microbiological culture, Gram staining, and modified acid-fast (Ziehl-Neelsen) staining for the identification of *Nocardia* species. **Results:** Gram staining of BAL fluid revealed thin, branched, beaded, filamentous, Gram-positive bacilli. Modified acid-fast staining identified branching acid-fast bacilli (1-2 organisms per high-power field (HPF)), consistent with *Nocardia*. Diagnosis of *Nocardia* is crucial as it necessitates targeted therapy, particularly in immunocompromised hosts. *Nocardia* was cultured after one week, highlighting its slow growth characteristic, which can delay diagnosis and treatment. The patient was commenced on trimethoprim-sulfamethoxazole (800/160 mg four times daily), showing significant clinical improvement within two weeks. After 12 months of treatment, there was complete resolution of symptoms, radiological improvement, and normalization of laboratory parameters, indicating successful treatment of pulmonary nocardiosis. **Conclusion:** Pulmonary nocardiosis must be considered in immunocompromised patients with persistent respiratory symptoms. Comprehensive imaging and bronchoscopy with BAL are pivotal for effective sample collection and accurate laboratory diagnosis. Modified Ziehl-Neelsen staining is critical for the definitive identification of *Nocardia* infection. Early and proactive screening in high-risk groups, such as HIV patients, cancer patients, or organ transplant recipients, is crucial for the prompt initiation of targeted therapy, typically with trimethoprim-sulfamethoxazole, to improve outcomes.

### INTRODUCTION

Nocardiosis is an uncommon infection caused by *Nocardia*, an aerobic actinomycete genus commonly found in soil environments. In the United States, approximately 500 to 1,000 cases of nocardiosis are diagnosed annually, though this number is likely an underestimate due to the inherent diagnostic challenges [1]. Approximately 60% of these infections involve individuals with pre-existing immune compromise, and incidence rates are expected to rise due to an expanding

immunocompromised population and improvements in molecular and microbiological diagnostic techniques [2]. The primary mode of transmission for pulmonary nocardiosis is through inhalation of contaminated soil particles, though ingestion or direct skin contact can also occur. Pulmonary nocardiosis is the most common form of this infection, typically affecting individuals with weakened immune systems, such as those with HIV infection, cancer, or those on prolonged glucocorticoid

therapy. The symptoms of nocardiosis often mimic those of other pulmonary infections, particularly tuberculosis, as well as presenting clinical manifestations that can resemble malignancy, infections by *Rhodococcus equi* in HIV-infected patients, or fungal infections like *Aspergillus* pneumonia, making accurate diagnosis challenging [3-5]. This diagnostic complexity leads to its characterization as a 'great masquerader' in clinical settings [6]. *Nocardia* species exhibit complex virulence mechanisms that enable them to evade immune responses, often presenting with clinical and radiological features similar to tuberculosis, especially in immunocompromised hosts. Through the production of enzymes like catalase and superoxide dismutase, they neutralize reactive oxygen species, thereby surviving inside macrophages where they can form granulomas, complicating differentiation from tuberculous granulomas. Additionally, *Nocardia* produces nocobactin, an iron-binding siderophore that facilitates its growth within the host, while biofilm formation further aids in its persistence and resistance to antimicrobial agents. These factors contribute significantly to the diagnostic challenges in distinguishing nocardiosis from tuberculosis in clinical settings [7, 8]. Given these complexities, timely recognition of nocardiosis is increasingly critical given the rising prevalence of immunosuppression, often associated with HIV infection, organ transplantation, and the use of biologic therapies.

With progressive immune system compromise, the ability to control infections diminishes, rendering patients more susceptible to opportunistic pathogens, notably *Nocardia* species. HIV infection markedly increases the incidence of nocardiosis, particularly when CD4 counts drop below 200 cells/ $\mu$ L. At counts under 100 cells/ $\mu$ L, individuals face an even greater risk due to profound immunosuppression. This association highlights the critical need for vigilant monitoring of CD4 levels in HIV patients to mitigate the risk of opportunistic infections like nocardiosis [9].

This case report underscores the diagnostic challenges posed by pulmonary nocardiosis, emphasizing the need for high clinical vigilance in immunocompromised patients presenting with respiratory symptoms. The nonspecific clinical presentation of nocardiosis, frequently in the absence of common respiratory pathogens such as *Mycobacterium tuberculosis*, can further complicate the diagnostic process. Therefore, definitive diagnosis depends on specialized laboratory techniques, including modified Ziehl-Neelsen staining and aerobic culture, to isolate and identify *Nocardia* species. The necessity for a prolonged incubation period to isolate *Nocardia* from clinical specimens, as well as considering nocardiosis in the differential diagnosis of atypical pulmonary infections in HIV-positive individuals, underscores the need for early recognition, appropriate diagnostic testing, and timely intervention. These steps are crucial to optimize patient outcomes and

prevent complications.

## CASE PRESENTATION

A 48-year-old male patient, diagnosed with a seizure disorder three months prior and on anti-epileptic medications (Levetiracetam and Clobazam) for the past three months, presented with a cough producing copious yellow-colored mucoid sputum, fever, and evening chills, which were alleviated by paracetamol 500 mg orally four times daily for the past two weeks. He also reported a weight loss of 3 kg over the previous month. There was no history of travel to endemic areas or prior opportunistic infections. He was newly diagnosed with HIV infection during this admission, with a CD4 count of 187 cells/ $\mu$ L and an HIV viral load of 34,283 copies/mL. Notably, the HIV diagnosis was triggered by these symptoms, underscoring the association of *Nocardia* infections with immunocompromised states. On general examination, the patient was moderately built, cooperative, and oriented to time, place, and person, with grade I clubbing. His blood pressure was 110/60 mmHg, with a pulse rate of 89 beats per minute and a respiratory rate of 18 breaths per minute. Systemic examination was unremarkable. Physical examination revealed right-sided crackles on lung auscultation, with no other significant findings.

## INVESTIGATIONS

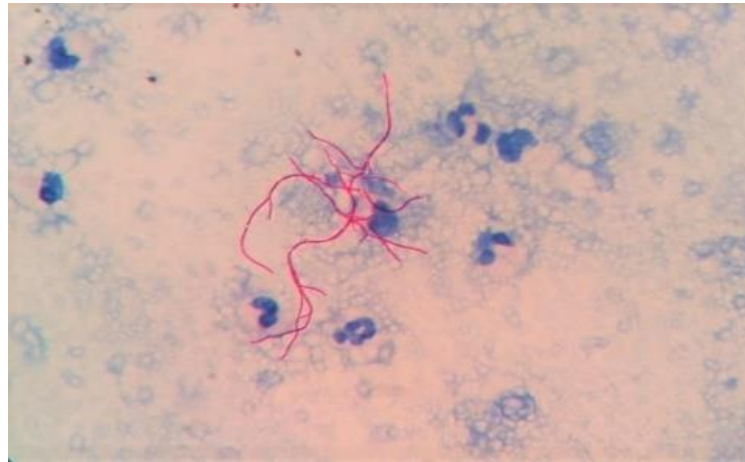
Initial laboratory tests revealed leukocytosis (15,800 cells/ $\mu$ L, 92% neutrophils) and an elevated erythrocyte sedimentation rate (90 mm/hr), indicative of an active inflammatory process. Blood cultures, fungal cultures, serological tests for common respiratory pathogens, and an autoimmune panel all returned negative results. The inclusion of an autoimmune panel in the diagnostic workup for suspected nocardiosis is crucial as it helps in distinguishing this infection from autoimmune or inflammatory conditions, especially in immunocompromised patients where clinical manifestations might mimic those of diseases like vasculitis or granulomatous disorders. Excluding autoimmune diseases such as systemic lupus erythematosus (SLE) or sarcoidosis allows clinicians to narrow their focus towards infectious etiologies like *Nocardia*. HIV testing conducted during this admission was positive for anti-HIV 1 antibodies, confirming the patient's new diagnosis of HIV infection.

Contrast-enhanced computed tomography (CT) of the thorax revealed multifocal, heterogeneously enhancing lesions in both lungs, predominantly in a peribronchovascular distribution. These lesions were surrounded by ground-glass opacities and accompanied by enlarged, necrotic mediastinal lymph nodes. These radiological findings, especially the pattern of lung involvement and the presence of necrotic lymphadenopathy, suggested an infectious process. Given the patient's immunocompromised status, pulmonary *Nocardia* infection was considered in the differential diagnosis.

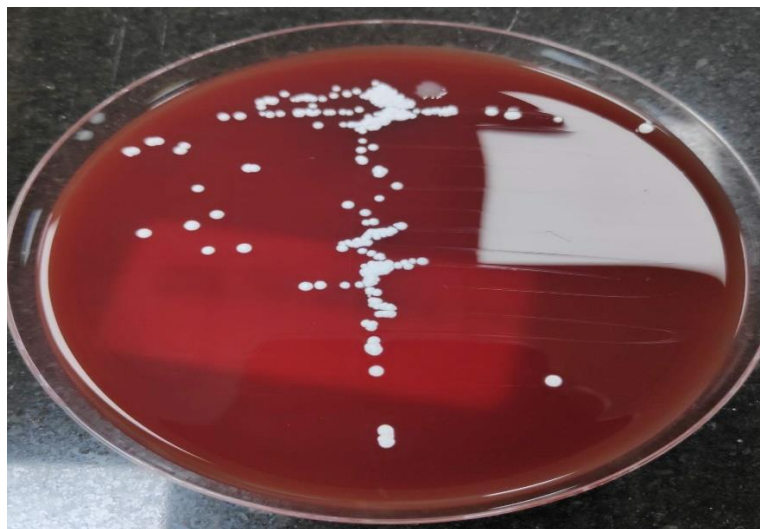
In contrast, these radiological features are less indicative of pulmonary tuberculosis, which typically manifests as well-defined cavitory lesions, primarily in the upper lobes. Furthermore, necrotic lymphadenopathy as observed in this case is less common in TB, which usually presents with caseating lymphadenopathy [10, 11]. Fungal infections like *Aspergillus* pneumonia might exhibit CT halos or air crescents, particularly in neutropenic patients; however, pulmonary *Nocardia* infection typically lacks these signs, presenting more diffusely in a peribronchovascular pattern. Additionally, lung malignancies often present as well-defined, necrotic masses with less surrounding inflammation and fewer ground-glass opacities compared to infections. These distinctions highlight the necessity for further diagnostic investigations to confirm the diagnosis.

Sputum culture for aerobic bacteria, incubated for 48 hours, yielded no growth. Sputum smear for acid-fast bacilli (AFB), using the Ziehl-Neelsen technique, was negative. Bronchoscopy demonstrated thick,

mucopurulent secretions throughout the tracheobronchial tree, more prominently on the right, further supporting an infectious process. BAL fluid was collected and submitted for microbiological analysis. Gram staining of the BAL fluid revealed numerous neutrophils and thin, branching, beaded, filamentous, Gram-positive bacilli. Modified Ziehl-Neelsen (ZN) staining, with 1% sulfuric acid decolorization, demonstrated filamentous, branching, acid-fast bacilli, morphologically consistent with *Nocardia* species (Figure 1). BAL fluid cultures produced dry, chalky white, adherent colonies on 5% sheep blood agar and dry, pale yellowish colonies on Sabouraud's dextrose agar after a week of aerobic incubation at 37°C (Figure 2). The isolate was confirmed as *Nocardia* species based on Gram staining, modified ZN staining, and a positive urease test. However, accurate species-level identification of *Nocardia*, which necessitates molecular methods [2], was not feasible in the current clinical setting. Drug susceptibility testing was also limited by the available diagnostic methods.



**Fig. 1.** Modified Ziehl-Neelsen (ZN) stained smear showing filamentous, branching acid-fast bacilli resembling *Nocardia* species (Magnification: 1000X)



**Fig. 2.** Dry, chalky-white colonies observed on 5% sheep blood agar after one week of aerobic incubation at 37°C.

## TREATMENT

Following the identification of *Nocardia*, treatment was initiated with Trimethoprim-sulfamethoxazole (TMP-SMX; 800/160 mg four times daily) and intravenous imipenem (500 mg four times daily, totaling 2-4 g/day) along with amikacin (350 mg twice daily, adjusted for body weight to achieve 15-20 mg/kg/day), in accordance with local guidelines for immunocompromised patients. TMP-SMX is widely regarded as the first-line treatment for nocardiosis; however, due to the variable antibiotic resistance profiles of *Nocardia* spp., initial empiric therapy with a combination of two or three agents is recommended, particularly in cases of severe infection. Severe nocardiosis includes cases of pulmonary disease with extensive lung involvement or with direct spread from the lung to the pleura, chest wall, or another contiguous organ. For most severe nocardial infections not involving the central nervous system, initial treatment typically includes TMP-SMX combined with imipenem and amikacin [12, 13].

Given the patient's clinical improvement, the dose of TMP-SMX was reduced to three times daily after four weeks, as prolonged high doses may elevate the risk of adverse effects, including bone marrow suppression or hepatotoxicity. No adverse effects were observed during the treatment course. The patient exhibited clinical improvement within two weeks of initiating therapy, specifically noting a decrease in cough and resolution of fever. After 21 days, with significant clinical progress, intravenous amikacin and imipenem were discontinued. Upon discharge after one month of hospitalization, he was prescribed oral TMP-SMX (800/160 mg three times daily) to continue for an additional 11 months.

Nocardiosis has a notable propensity for hematogenous dissemination, potentially affecting nearly any organ system, especially the central nervous system, and exhibits a tendency for relapse or progression even after initial treatment. Consequently, the duration of treatment is often extended to minimize the risk of relapse. Immunocompetent patients with pulmonary or multifocal (non-CNS) nocardiosis typically require 6 to 12 months of antimicrobial therapy. However, immunocompromised individuals and those with CNS involvement necessitate at least 12 months of therapy, accompanied by rigorous clinical monitoring [14]. The patient's response to treatment was closely monitored through monthly outpatient department (OPD) visits, where inflammatory markers (C-reactive protein [CRP] and erythrocyte sedimentation rate [ESR]), complete blood count (CBC), liver function tests, and chest radiographs were reviewed to gauge therapeutic response, identify adverse effects, and guide necessary treatment adjustments.

Due to his new diagnoses of HIV and pulmonary nocardiosis, the patient was prescribed tenofovir disoproxil fumarate (TDF), lamivudine (3TC), and dolutegravir (DTG) as first-line antiretroviral therapy (ART), a month after initiating antimicrobial therapy for

nocardiosis, due to its efficacy, the low potential for drug interactions, and the strategy to mitigate the risk of immune reconstitution inflammatory syndrome (IRIS). He received counseling on managing potential drug interactions between his antiretroviral regimen and trimethoprim-sulfamethoxazole, focusing on monitoring for overlapping toxicities. To enhance treatment adherence and facilitate continuous care, he was referred to a local district hospital for the initiation of ART.

## OUTCOME

After 12 months of treatment, the patient achieved complete symptom resolution, radiological clearance of pulmonary lesions, and normalization of laboratory markers, signifying successful treatment of pulmonary nocardiosis. Laboratory parameters normalized, evidenced by a leukocyte count reduction to 10,184 cells/mm<sup>3</sup>, an erythrocyte sedimentation rate of 14 mm/hr, and a C-reactive protein level of 0.8 mg/L, reflecting the resolution of inflammation and infection. Follow-up chest radiography confirmed the resolution of consolidation, pulmonary infiltrates, and previously observed necrotic lymphadenopathy, as assessed by a radiologist. Radiological assessments indicated improvement through decreased infiltrate density and reduced lymph node size. Subsequent CT scans provided further evidence of a positive therapeutic response with the resolution of ground-glass opacities. Throughout the treatment course, the patient was closely monitored for potential adverse effects, including regular assessments of liver and kidney function, hematologic parameters, and signs of drug toxicity. Mild gastrointestinal disturbances, including nausea and vomiting, occurred but were effectively managed with antiemetic therapy. Monthly outpatient evaluations confirmed no clinically significant adverse effects throughout the treatment duration. His cough, dyspnea, and fever resolved completely. Serial BAL cultures, conducted biweekly post-initiation of therapy, were negative for *Nocardia* growth by week 16, corroborating successful microbial eradication. This observation corroborates existing data on the clearance timeline in immunocompromised hosts, where *Nocardia* may remain culturable for weeks. Negative cultures by week 16 underscore the efficacy of extended antimicrobial regimens and highlight the critical role of ongoing microbiological surveillance.

Immunocompromised patients with HIV face increased long-term risks, notably the potential for nocardiosis relapse. Therefore, continuous clinical and microbiological monitoring is imperative for the early detection and effective management of potential recurrence. The patient's long-term prognosis hinges on successful immune reconstitution through ART. Concurrently, adherence to therapy is critical in minimizing the risk of reinfection.

## DISCUSSION

Nocardial infections are known to have a pattern of remission and recurrence. The heightened susceptibility to nocardial infections in individuals with impaired cell-mediated immunity [4, 15, 16] highlights the essential function of T-cell responses in containing *Nocardia*, as these organisms are intracellular pathogens that thrive in environments where this immune component is deficient. Several conditions can impair cell-mediated immunity, increasing susceptibility to nocardiosis. Conditions known to compromise cell-mediated immunity, thereby elevating the risk for nocardiosis, encompass HIV infection, organ transplantation, chronic obstructive pulmonary disease (COPD), alcoholism, and corticosteroid therapy [16]. Each of these conditions either depletes T-cell numbers or impairs their function.

Sakyi *et al.* (2018) documented a significantly higher incidence of *Nocardia* coinfection in HIV-positive individuals than tuberculosis in Ghana, underscoring *Nocardia*'s substantial impact on this patient demographic [17]. Similarly, Hoza *et al.* (2017) identified a notable prevalence of *Nocardia* infections in Northern Tanzania, especially among HIV patients with respiratory symptoms, with rates approaching those of tuberculosis [18]. Studies from Brazil and Iran (Baio *et al.*, 2013; Ekrami *et al.*, 2014) have also emphasized the prevalence of *Nocardia* among immunocompromised individuals, especially those co-infected with tuberculosis [19, 20]. In contrast to global trends, regional studies within the United States reveal different patterns, with invasive nocardiosis being particularly predominant among transplant recipients, illustrating how prevalence can vary markedly by region and population.

The similarity in clinical manifestations between nocardiosis and pulmonary tuberculosis often leads to misdiagnosis, thereby exacerbating morbidity and increasing mortality rates. Diagnostic confusion is evidenced by research indicating that between 10% and 15% of pulmonary nocardiosis cases are misdiagnosed as tuberculosis due to overlapping clinical and radiological features in regions where tuberculosis is highly endemic, highlighting the critical need for implementing advanced differential diagnostic strategies, including molecular techniques and microbial cultures, to distinguish between these two infections [21, 22]. In a similar vein, research from India found that 25% of suspected TB cases with negative AFB smears were confirmed to have pulmonary nocardiosis upon further investigation with culture-based methods or molecular diagnostics [23].

Pulmonary nocardiosis presents with diverse radiological manifestations, including single or multiple nodules, lung masses (with or without cavitation), reticulonodular infiltrates, interstitial infiltrates, lobar consolidation, subpleural plaques, and pleural effusions. The broad spectrum of radiological features in pulmonary nocardiosis complicates its differentiation from other respiratory conditions like tuberculosis, fungal infections,

or neoplasms, often necessitating further diagnostic tests [24].

Accurate laboratory diagnosis relies on high-quality samples, meticulous microscopy, and appropriate culture techniques. Invasive sampling methods like BAL, bronchial aspirates, and endotracheal aspirates are recognized for their superior yield in isolating *Nocardia*, as demonstrated in recent studies [25]. However, culture remains the gold standard for definitive diagnosis of pulmonary nocardiosis [26]. The cultivation of *Nocardia* on solid media presents challenges due to its slow growth rate, typically taking between 5 to 21 days, and the frequent issue of contamination by faster-growing respiratory flora, which can obscure *Nocardia* identification [27]. Due to the extended incubation period required for *Nocardia* isolation from clinical specimens, infections are frequently missed in routine diagnostics. It is imperative that cultures are maintained for a minimum of 14 days to increase the likelihood of *Nocardia* detection, as shorter periods might result in false negatives [2]. Although molecular techniques such as PCR facilitate expedited diagnosis, their implementation is limited by availability, underscoring the need for enhanced access to these technologies in clinical microbiology labs [4]. In resource-limited settings, this case highlights the challenges in diagnosing and treating nocardiosis without advanced diagnostic tools. Given the delays in definitive diagnosis, clinicians might be compelled to initiate empirical antimicrobial therapy, guided by clinical presentation and knowledge of local disease patterns. This case underscores the urgent need for improved diagnostic infrastructure and ongoing education for healthcare professionals to enhance early recognition of nocardiosis, particularly in immunocompromised populations, thereby improving patient outcomes and informing public health strategies.

TMP-SMX remains the preferred antimicrobial therapy for nocardiosis. In instances of sulfonamide intolerance or resistance, alternative or additional agents like minocycline, amikacin, or beta-lactams (cefotaxime, ceftriaxone) and carbapenems (imipenem) are considered, ideally guided by susceptibility testing [16]. Combination therapy might be necessary for severe infections or to cover potential resistance. For severe nocardiosis, initial therapy with intravenous co-administration of TMP-SMX and a combination of a carbapenem and/or amikacin is generally recommended by infectious disease specialists. The initial intravenous regimen is recommended for at least 3-6 weeks, extending until clinical improvement is confirmed, with consideration for longer durations in immunocompromised patients [5]. Although *in vitro* studies suggest imipenem's superior activity against some *Nocardia* strains compared to other carbapenems [28], comparative clinical studies are scarce, underscoring the need for further research to guide therapeutic choices.

Treatment duration for nocardiosis is typically determined by the patient's immunological competence,

infection severity, and clinical response to therapeutic interventions. Immunocompromised patients may require extended therapy courses and more intensive surveillance to mitigate the risk of relapse or complications. Follow-up protocols necessitate periodic clinical evaluations, radiographic imaging, and microbiological cultures, ideally at 3-month intervals initially, to assess therapeutic efficacy and detect early signs of recurrence or complications. Tailoring the therapeutic and follow-up approach to these patient-specific factors is critical for achieving successful outcomes [12].

Clinical improvement is generally observed within two weeks post-initiation of therapy; failure to respond should lead to an immediate reevaluation of potential resistance. A decade-long study by Udhe *et al.* (2010) revealed that approximately 42% of 765 *Nocardia* isolates exhibited resistance to trimethoprim-sulfamethoxazole, highlighting an emerging resistance issue. Resistance to primary therapeutic agents like trimethoprim-sulfamethoxazole occurs in up to 40% of cases. This resistance leads to treatment failures, extended disease courses, and increased relapse rates. While alternative antibiotics such as carbapenems, amikacin, and linezolid can be effective, their application is often curtailed by adverse effects. Enhanced resistance profiling, potentially available at specialized centers, should be considered standard for severe or refractory cases. Implementing routine susceptibility testing could significantly enhance therapeutic outcomes, especially in areas with elevated nocardiosis prevalence [28].

Given the patient's symptoms of fever, productive cough, weight loss, and necrotic lymphadenopathy, coupled with his immunocompromised state due to HIV, pulmonary tuberculosis was initially suspected. Radiological signs like ground-glass opacities and enhancing lesions typically suggest infection but are not specific to TB, thus complicating the differential diagnosis with conditions like nocardiosis. Although the AFB smear was negative, which lessens the likelihood of tuberculosis, the presence of necrotic lymphadenopathy and ground-glass opacities necessitated exploration of other pathogens like *Nocardia*. In this scenario, BAL and modified Ziehl-Neelsen staining proved pivotal for the identification of *Nocardia* species, highlighting the critical role of these diagnostic techniques in managing immunocompromised patients, particularly those newly diagnosed with HIV.

TMP-SMX was selected as the first-line therapy, reflecting its status as the treatment of choice for nocardiosis due to its well-documented effectiveness, particularly in the immunocompromised population. However, the lack of species-level identification and comprehensive drug susceptibility testing could potentially affect the optimization of therapy, highlighting a need for enhanced microbiological capabilities. Given his HIV-positive status, potential drug-drug interactions with antiretroviral agents were meticulously evaluated,

underscoring the critical role of regimen compatibility and patient adherence in achieving therapeutic success. Despite these diagnostic and therapeutic challenges, the patient's condition improved significantly, supporting the effectiveness of the chosen regimen [3].

A critical aspect of nocardiosis management, especially in immunocompromised individuals, is the significant risk of recurrence, which mandates comprehensive, extended follow-up care. Regular clinical evaluations, alongside imaging and microbial cultures at three to six-month intervals, are essential for early relapse detection and effective management. For patients with HIV, vigilant follow-up is imperative due to the complexities introduced by ART-induced IRIS, which can either worsen nocardiosis or mimic its symptoms, complicating disease management [14].

This case underscores the necessity for rapid diagnostic evaluation and the immediate commencement of targeted antimicrobial therapy like TMP-SMX in patients with compromised immune systems. Implementing this therapeutic strategy resulted in clinical improvement of nocardiosis and effective management of HIV-induced immunosuppression. Moreover, this case study illustrates the importance of an integrated medical approach, emphasizing careful selection of antiretroviral agents to avoid adverse interactions with nocardiosis treatment, ensuring holistic management of both conditions.

Future research should focus on developing rapid molecular diagnostic tools to expedite nocardiosis detection, thereby minimizing diagnostic delays. For example, recent advancements in real-time PCR and next-generation sequencing technologies are promising for their ability to quickly identify *Nocardia* species, as evidenced by studies [29, 30], potentially transforming early diagnosis in clinical practice.

Although this case study provides valuable insights, its findings are constrained by the inherent limitations of single-case analyses. Generalizations from a single case might not capture the diverse manifestations of nocardiosis across different populations, underscoring the need for broader epidemiological studies. To develop specialized treatment protocols for immunocompromised individuals and fully understand the complexities of *Nocardia* infections, this highlights the imperative for comprehensive research to elucidate *Nocardia* infection dynamics in varied clinical and demographic contexts.

This case highlights the need to consider nocardiosis in the differential diagnosis of suspected tuberculosis, especially in immunocompromised patients with negative AFB smears. Early adoption of specific diagnostic techniques like modified acid-fast staining or molecular assays is critical for accurate identification, given the symptomatic and radiographic similarities between nocardiosis and tuberculosis. This approach aids in reducing misdiagnosis rates. Effective communication with microbiology labs about potential nocardiosis cases

is vital for implementing prolonged culture techniques. These strategies facilitate prompt treatment, decrease complications, and enhance patient outcomes. The marked clinical improvement observed in our patient on TMP-SMX therapy supports its efficacy, highlighting the importance of timely and appropriate antibiotic selection.

## ACKNOWLEDGMENT

This research did not receive any specific grant from funding agencies in the public, commercial, or not-for-profit sectors. Written informed consent for publication was obtained from the patient. This case report was conducted in accordance with the ethical guidelines of K S Hegde Medical Academy (Nitte Deemed to be University) and was determined by the K S Hegde Medical Academy Institutional Ethics Committee (IEC) to not require full IEC review.

## CONFLICTS OF INTEREST

The authors declare that there are no conflicts of interest associated with this manuscript.

## REFERENCES

1. U.S. Centers for Disease Control and Prevention (CDC). (2024, May 2). About Nocardiosis. United States Government. Accessed 2024, November 5. Retrieved from: <https://www.cdc.gov/nocardiosis/about/index.html>
2. U.S. Centers for Disease Control and Prevention (CDC). (2024, May 2). Clinical Overview of Nocardiosis. United States Government. Accessed 2024, November 5. Retrieved from: <https://www.cdc.gov/nocardiosis/hcp/clinical-overview/index.html>
3. Guerra AC, Batista D, Aleixo MJ, Saraiva P, Aguas MJ. Disseminated Nocardiosis: A Successful Blind Strategy of Treatment in an HIV Infected Patient. *Case Rep Infect Dis*. 2015; 2015: 260640.
4. González-Jiménez P, Méndez R, Latorre A. Pulmonary Nocardiosis. A case report. *Rev Esp Quimioter*. 2022; 35 Suppl 1: 114-116.
5. Brown-Elliott BA, Brown JM, Conville PS, Wallace RJ. Clinical and laboratory features of the *Nocardia* spp. based on current molecular taxonomy. *Clin Microbiol Rev*. 2006; 19 (2): 259–82.
6. Duggal SD, Chugh TD. Nocardiosis: A Neglected Disease. *Med Princ Pract*. 2020; 29 (6): 514-23.
7. Engelbrecht A, Saad H, Gross H, Kaysser L. Natural Products from *Nocardia* and Their Role in Pathogenicity. *Microb Physiol*. 2021; 31 (3): 217.
8. Arai MA, Ebihara I, Makita Y, Hara Y, Yaguchi T, Ishibashi M, et al. Isolation of nobactin NAs as Notch signal inhibitors from *Nocardia farcinica*, a possibility of invasive evolution. *J Antibiot (Tokyo)*. 2021; 74 (4): 255-9.
9. Abbasian L, Dehghan Manshadi SA, Hassan Nezhad M, Masoumzadeh N, Ghaderkhani S, Keyvanfar A, et al. A Case Report of Disseminated Nocardiosis in a Patient with HIV Infection: Concurrent Liver, Pulmonary, and Brain Involvements. *Arch Clin Infect Dis*. 2024; 19 (2): e140527.

10. Gonzalez LM, Venkatesan R, Amador P, Sanivarapu RR, Rangaswamy B. TB or Not TB: Lung Nocardiosis, a Tuberculosis Mimicker. *Cureus*. 2024; 16 (3): e55412.
11. Chen J, Zhou H, Xu P, Zhang P, Ma S, Zhou J. Clinical and radiographic characteristics of pulmonary nocardiosis: clues to earlier diagnosis. *PLoS One*. 2014; 9 (3): e90724.
12. Restrepo A, Clark NM, Infectious Diseases Community of Practice of the American Society of Transplantation. *Nocardia* infections in solid organ transplantation: Guidelines from the Infectious Diseases Community of Practice of the American Society of Transplantation. *Clin Transplant*. 2019; 33: e13509.
13. Clark NM, Reid GE, AST Infectious Diseases Community of Practice. *Nocardia* infections in solid organ transplantation. *Am J Transplant*. 2013; 13 Suppl 4: 83-92.
14. Wilson JW. Nocardiosis: updates and clinical overview. *Mayo Clin Proc*. 2012; 87 (4): 403-7.
15. Wadhwa T, Baveja U, Kumar N, Govil D, Sengupta S. Clinical manifestations of nocardiosis: study of risk factors and outcomes in a tertiary care hospital. *J Lab Physicians*. 2017; 9 (4): 288-95.
16. De S, Desikan P. Pulmonary nocardiosis mimicking relapse of tuberculosis. *BMJ Case Rep*. 2009; 2009: bcr0620080233.
17. Sakyi SA, Danquah KO, Ephraim RD, Enimil A, Frimpong V, Ahenkorah Fondjo L, et al. Evaluating the Contribution of *Nocardia* spp. and *Mycobacterium tuberculosis* to Pulmonary Infections among HIV and Non-HIV Patients at the Komfo Anokye Teaching Hospital, Ghana. *Can J Infect Dis Med Microbiol*. 2018; 2018: 2910198.
18. Hoza AS, Mfinanga SGS, Moser I, König B. Isolation, biochemical and molecular identification of *Nocardia* species among TB suspects in northeastern Tanzania; A forgotten or neglected threat? *BMC Infect Dis*. 2017; 17 (1): 407.
19. Baio PVP, Ramos JN, dos Santos LS, Soriano MF, Ladeira EM, Souza MC, et al. Molecular identification of *Nocardia* isolates from clinical samples and an overview of human nocardiosis in Brazil. *PLoS Negl Trop Dis*. 2013; 7 (12): e2573.
20. Ekrami A, Khosravi AD, Samarbaft-Zadeh AR, Hashemzadeh M. *Nocardia* co-infection in patients with pulmonary tuberculosis. *Jundishapur J Microbiol*. 2014; 7 (12): e12495.
21. Gupta S, Grant LM, Powers HR, et al. Invasive *Nocardia* Infections across Distinct Geographic Regions, United States. *Emerg Infect Dis*. 2023; 29 (12): 2417-25.
22. Deshmukh A, Kurup R, Nair A, Sugathan A, Nath AB, Ramachandran A. Uncommon and Unusual Pathogen – A Case of Pulmonary and Cutaneous Nocardiosis. *J Med Sci Clin Res*. 2020; 8 (11): 521-5.
23. Singh A, Sandhu RS, Agnihotri R, Kumar R, Jain S, Singh S. Pulmonary Nocardiosis: Clinical Profile, Diagnosis, and Outcome in Patients Presenting as Suspected Tuberculosis. *Lung India*. 2020; 37 (4): 306-10.
24. Lerner PI. Nocardiosis. *Clin Infect Dis*. 1996; 22 (6): 891–905.
25. Georghiou PR, Blacklock ZM. Infection with *Nocardia* species in Queensland. A review of 102 clinical isolates. *Med J Aust*. 1992; 156 (10): 692–7.
26. Gutiérrez C, Céspedes A, Legarraga P, Morales P, Chanqueo

Ashraf et al.

L. Infection by *Nocardia cyriacigeorgica* in a patient with HIV infection in the AIDS stage. *Rev Chil Infectol.* 2020; 37 (3): 322-6.

27. Manoharan H, Selvarajan S, Sridharan KS, Sekar U. Pulmonary Infections Caused by Emerging Pathogenic Species of *Nocardia*. *Case Rep Infect Dis.* 2019; 5184386.

28. Udhe KB, Pathak S, McCullum I, Jannat-Khah DP, Shadommy SV, Dykewicz CA, et al. Antimicrobial-Resistant *Nocardia* Isolates, United States, 1995–2004. *Clin Infect Dis.*

2010; 51 (12): 1445-8.

29. Weng SS, Zhang HY, Ai JW, Gao Y, Liu YY, Xu B, et al. Rapid Detection of *Nocardia* by Next-Generation Sequencing. *Front Cell Infect Microbiol.* 2020; 10: 13.

30. Lafont E, Conan PL, Rodriguez-Nava V, Lebeaux D. Invasive Nocardiosis: Disease Presentation, Diagnosis and Treatment - Old Questions, New Answers? *Infect Drug Resist.* 2020; 13: 4601-13.

**Cite this article:**

---

Ashraf AA, Bhat UP. Nocardiosis: An Essential Diagnostic Challenge in Suspected Pulmonary Tuberculosis. *J Med Microbiol Infect Dis*, 2024; 12 (3): 235-242. DOI: 10.61186/JoMMID.12.3.235.