

Mucormycosis: An Emerging Fungal Infection in the COVID-19 Pandemic

Parisa Saberi-Hasanabadi^{1,2} , Milad Esmailzadeh Farmad³ , Ramin Ataee^{4*} 

¹Ph.D in Toxicology and pharmacology, Faculty of pharmacy, Mazandaran University of Medical Sciences, Sari, Iran; ²Student Research Committee, Mazandaran University of Medical sciences, Sari, Iran; ³9th Dey of Torbat Heydariyeh Hospital, Mashhad University of Medical Sciences, Mashhad, Iran; ⁴Medicinal Plants Research Center, Mazandaran University of Medical Sciences, Sari, Iran

ARTICLE INFO

Review Article

Keywords: COVID-19 infections, Mucormycetes, Organ damage, Risk factors and linkages

Received: 03 Jun. 2023

Received in revised form: 21 Aug. 2024

Accepted: 31 Jul. 2024

DOI: 10.61186/JoMMID.12.2.84

*Correspondence

Email: raminataee1349@gmail.com

Tel: +989113232804

Fax: +981133543084

© The Author(s)



ABSTRACT

During the COVID-19 pandemic, there has been a resurgence of mucormycosis, a rare and opportunistic fungal infection, with India reporting a particularly notable increase in incidence. Mucormycosis is a life-threatening condition that requires prompt diagnosis and treatment to prevent high mortality rates and severe sequelae. It is caused by the inhalation of spores from ubiquitous filamentous fungi belonging to the order Mucorales. Individuals with compromised immune systems or underlying conditions, such as diabetes, ketoacidosis, and neutropenia, are particularly vulnerable to infection. The risk and severity of mucormycosis are exacerbated by several factors, including corticosteroid therapy, prolonged intensive care stay, and the use of ventilators. Additionally, contaminated oxygen humidifiers pose a significant risk. Effective management of mucormycosis in critically ill COVID-19 patients relies on early diagnosis, optimization of predisposing factors, timely antifungal treatment, surgical debridement, and adjuvant therapies. Imaging modalities such as contrast-enhanced CT scans and MRI are crucial for guiding surgical debridement and assessing disease extent. This review article provides a comprehensive overview of the clinical pathogenesis, risk factors, diagnosis, treatment, and challenges associated with mucormycosis in COVID-19 patients, summarizing the latest findings in this field.

INTRODUCTION

Mucormycosis, a rare and life-threatening fungal infection, is caused by mucormycetes, an order of ubiquitous molds found in diverse environments. The most common species responsible for human mucormycosis belong to the genera *Rhizopus*, *Mucor*, and *Lichtheimia* [1]. Although severe, mucormycosis often goes underreported, hindering a comprehensive understanding of its epidemiology. Existing evidence, however, indicates that individuals with underlying conditions are disproportionately affected. These conditions include diabetes mellitus, a frequently associated factor, as well as immunodeficiency disorders, hematological malignancies, and a history of allogeneic stem cell transplantation. These high-risk populations are more susceptible to mucormycosis due to a complex interplay of factors, including compromised immune systems, dysregulated iron metabolism, and the presence of comorbidities. This underscores the importance of heightened awareness and vigilance in these groups [2].

Existing literature on the epidemiology of mucormycosis is limited, characterized by a scarcity of large-scale, population-based studies. This lack of standardized case definitions and robust diagnostic criteria across studies, coupled with heterogeneity in study design and population characteristics, makes it difficult to compare findings and draw definitive conclusions about the true incidence, prevalence, and risk factors for mucormycosis. These methodological inconsistencies hinder the ability to establish reliable epidemiological data on mucormycosis. Therefore, future research should prioritize standardized case definitions, robust diagnostic criteria, and large-scale, prospective studies to accurately assess the burden and risk factors associated with this infection, particularly in the context of the COVID-19 pandemic [1–3].

While previous research has established the susceptibility of immunocompromised individuals to mucormycosis [4], the COVID-19 pandemic has brought a renewed urgency to understanding this invasive fungal

infection and improving its management. This pandemic has highlighted the complex interplay between viral infections, immune dysregulation, and opportunistic infections. Diabetes mellitus, encompassing type 1, type 2, and secondary diabetes, is a well-established predisposing factor for mucormycosis, with studies reporting a prevalence of 30% to 80% among individuals with mucormycosis [1, 5]. The widespread use of corticosteroids in severe COVID-19, coupled with the virus's potential to induce transient hyperglycemia, further complicates this relationship and may contribute to the observed increase in mucormycosis cases. Further research is warranted to elucidate the specific mechanisms underlying this interaction and to develop targeted preventive and therapeutic strategies for COVID-19 patients at risk [2].

Mucormycosis typically develops following the inhalation of fungal spores from the environment, with the sinuses and lungs being the most common primary sites of infection. However, deep skin trauma, particularly burns and necrotizing wounds, can also provide a portal of entry for the fungus, increasing the risk of developing mucormycosis. Mucormycosis is caused by a group of fungi belonging to the order Mucorales. These fungi are ubiquitous, commonly found in soil, decaying vegetation, and dead animal matter. Although Mucorales are widespread in the environment, infection primarily occurs through respiratory inhalation of spores, with skin contact playing a less frequent role [6, 7]. Given that inhalation of spores is the most common mode of transmission, airborne precautions are paramount in high-risk settings, particularly in wards with immunocompromised patients, and construction sites where soil disruption is common [2].

The COVID-19 pandemic has underscored the complex interplay between the immune system and infectious diseases. Severe acute respiratory syndrome coronavirus 2 (SARS-CoV-2), the causative agent of COVID-19, employs multiple mechanisms to evade and manipulate the host's immune response, leading to immune dysregulation and aberrant inflammation [8]. This dysregulation can predispose individuals to secondary infections, including mucormycosis. SARS-CoV-2 infection can trigger a cascade of events that disrupt the delicate balance of the immune system, leading to impaired immune function. This risk is particularly pronounced in severe COVID-19 cases, where the presence of multiple risk factors, including glucocorticoid therapy, uncontrolled diabetes, prolonged ICU stays, and underlying health conditions, can further disrupt immune responses, increasing susceptibility to opportunistic infections like mucormycosis [9, 10]. Importantly, while mucormycosis is a serious concern, it remains a relatively rare complication of COVID-19.

Mucormycosis is not transmissible from person to person. Infection arises from environmental exposure, primarily through the inhalation of fungal spores present

in soil, decaying vegetation, or other organic matter. Less commonly, infection can occur through direct contact of the fungus with broken skin or mucous membranes. Once established, mucormycosis can disseminate to various organs, most commonly the nasal mucosa, sinuses, eyes, lungs, and brain, leading to severe and potentially life-threatening complications. Prompt treatment is essential and typically involves a multifaceted approach that includes antifungal therapy, often with intravenous liposomal amphotericin B as the initial choice, and surgical debridement of necrotic tissue. The extent of surgical intervention depends on the severity and location of the infection [8, 9, 11].

Highlighting the increased susceptibility to mucormycosis among COVID-19 patients, Dubey *et al.* (2021) conducted an observational study to characterize the clinical features of this fungal infection in individuals with a history of COVID-19, diabetes, and steroid use for SARS-CoV-2 infection. Their analysis of 55 consecutive confirmed cases of mucormycosis revealed that middle-aged diabetic men with COVID-19 were disproportionately affected. Notably, these individuals experienced a higher frequency of complications, particularly rhino-orbital-cerebral mucormycosis and cranial nerve palsies, often resulting in visual impairments [12].

Clinical manifestations of mucormycosis are diverse, varying depending on the site of infection. Common presenting symptoms include facial pain or swelling, nasal congestion or discharge, headache, fever, cough, chest pain, and visual disturbances. Given the potential severity of mucormycosis, these symptoms warrant prompt diagnostic evaluation. Timely detection and management of this invasive fungal infection necessitate a comprehensive diagnostic approach. The gold standard for definitive diagnosis remains the isolation of the fungus through culture and/or histopathological examination of biopsy specimens. However, imaging techniques and molecular analysis play crucial complementary roles. Specifically, diagnostic tools include direct microscopy, histopathology, fungal culture, molecular diagnostics (*e.g.*, PCR), and imaging studies (*e.g.*, CT scans and MRI) tailored to the suspected site of infection (*e.g.*, lungs, sinuses, brain) [11, 12].

This review aims to provide a comprehensive overview of mucormycosis in the context of the COVID-19 pandemic, with a particular focus on summarizing the identified risk factors, diagnostic challenges, and treatment strategies. Diagnosing mucormycosis can be challenging, as traditional methods like culture and microscopy can lack sensitivity, particularly in early stages of the disease. Moreover, managing mucormycosis often necessitates a complex, multimodal approach involving antifungal therapy, surgical debridement, and supportive care. This complexity, coupled with the often-advanced stage at diagnosis, contributes to the persistent therapeutic challenges and the persistently high mortality

rate associated with mucormycosis. This review seeks to synthesize current knowledge regarding these challenges and provide a comprehensive overview of mucormycosis in the context of the COVID-19 pandemic.

Literature search

A comprehensive literature search was conducted using major databases including PubMed, Scopus, Web of Science, and Embase to identify relevant articles published in English up to August 28, 2023. The initial search was performed on May 30, 2021, and subsequently updated to ensure inclusion of the most recent publications. The search strategy incorporated a combination of keywords and MeSH terms relevant to COVID-19 and mucormycosis, including "COVID-19," "Mucormycosis," "Risk factors," "Organ damage," and "Methods of diagnosis and treatment." This iterative search yielded a total of 108 relevant articles, encompassing original research, reviews, and case reports, which were deemed suitable for inclusion in this review.

Origin of mucormycosis

Mucormycetes are ubiquitous fungi found in various environmental niches, particularly soil and decaying organic matter like leaves, compost piles, and animal dung. These fungi are notable year-round, with increased abundance observed during the summer and autumn months. This seasonal pattern underscores the importance of environmental exposure in the context of mucormycosis. For instance, a study analyzing weather patterns in Beirut, Lebanon, identified a correlation between a series of invasive mucormycosis outbreaks and the conclusion of a hot, dry period spanning May to October [13].

Although Mucorales spores are ubiquitous in the environment, rendering complete avoidance impractical, the risk of developing mucormycosis is not uniform. Individuals with compromised immune systems face a significantly higher risk of infection. Studies have consistently shown that healthy individuals with robust immunity are less likely to contract mucormycosis. In contrast, individuals with pre-existing conditions such as diabetes, hematological malignancies, immunodeficiency disorders, or those who have undergone organ transplantation are disproportionately affected by this fungal infection. It is important to note that even individuals without apparent immune compromise can be at risk under specific circumstances. For instance, inhaling a high concentration of spores from contaminated soil or having direct contact with Mucorales on contaminated material, particularly in the setting of a wound or burn, can increase the risk of infection [14, 15].

Mucormycosis is caused by a group of fungi belonging to the order Mucorales, commonly referred to as mucormycetes. Among the Mucorales, *Rhizopus* and

Mucor species are the most common causative agents of mucormycosis [13, 16, 17]. However, other fungi within this order can also cause this infection, including *Lichtheimia*, *Syncephalastrum*, and *Cunninghamella* species. It is important to distinguish mucormycosis from other fungal infections, such as mucosal candidiasis, aspergillosis, and *Pneumocystis jirovecii* pneumonia, which are caused by different fungal pathogens [14].

The global distribution of mucormycosis is not uniform, with varying prevalence rates observed across different countries [15]. For instance, India reported over 47,000 cases between May and July 2021, highlighting a disproportionately high burden of disease and emphasizing the urgent need for enhanced surveillance, early diagnosis, and access to antifungal treatment in this region. Although mucormycosis has traditionally been more prevalent in developing countries, affecting primarily individuals with uncontrolled diabetes, and in developed countries, affecting those who have undergone hematopoietic stem cell or solid organ transplantation, the COVID-19 pandemic has revealed a concerning rise in cases among post-COVID-19 patients, irrespective of prior health status [18].

Mucormycosis outbreak

It is crucial to emphasize that mucormycosis is not contagious and does not spread through person-to-person contact. This opportunistic invasive fungal infection typically affects individuals with compromised immune systems. Mucormycosis can manifest in various forms, including rhinocerebral, pulmonary, cutaneous, and gastrointestinal mucormycosis.

Risk factors for mucormycosis can vary geographically and have evolved in the context of the COVID-19 pandemic. In developed countries, underlying malignancies and hematopoietic stem cell transplantation remain major risk factors for mucormycosis [7]. Globally, uncontrolled diabetes is a well-established risk factor for mucormycosis, and this risk is particularly pronounced in individuals with COVID-19, especially in developing countries. The co-occurrence of COVID-19 and uncontrolled diabetes appears to significantly increase the risk of mucormycosis, often referred to as "COVID-19-associated mucormycosis" (CAM), leading to severe clinical outcomes and prolonged hospitalization [19].

This increased risk is likely due to the complex interplay between diabetes, COVID-19, and the immune system. In individuals with diabetes, COVID-19 infection can trigger a dysregulated immune response characterized by prolonged inflammation, impaired immune cell function, and increased susceptibility to secondary infections, including mucormycosis [20]. Specifically, COVID-19 infection can lead to hyperglycemia and ketoacidosis, particularly in individuals with poorly controlled diabetes. These metabolic derangements create

an environment conducive to fungal growth and invasiveness. Additionally, both COVID-19 and corticosteroid therapy, often used to manage severe COVID-19, can suppress the immune system, further increasing vulnerability to opportunistic infections like mucormycosis [20].

While mucormycosis is most commonly observed in individuals with compromised immunity, it is important to note that it can also affect individuals with normal immune function. However, the clinical presentation and distribution of affected sites may differ in these individuals. For instance, approximately 50% of cutaneous mucormycosis cases occur in the absence of

underlying conditions [21]. Cutaneous mucormycosis, although less common than other forms like rhino-orbital-cerebral mucormycosis, often manifests in immunocompetent individuals following trauma or skin barrier disruption (Fig. 1).

Although not absolute, certain patterns are observed in site-specific infection depending on the host's underlying health status. For example, while the skin is more frequently affected in immunocompetent individuals, in contrast, the paranasal sinuses are commonly involved in diabetic patients, and the lungs are often affected in those who have undergone hematopoietic stem cell transplantation [22-24].

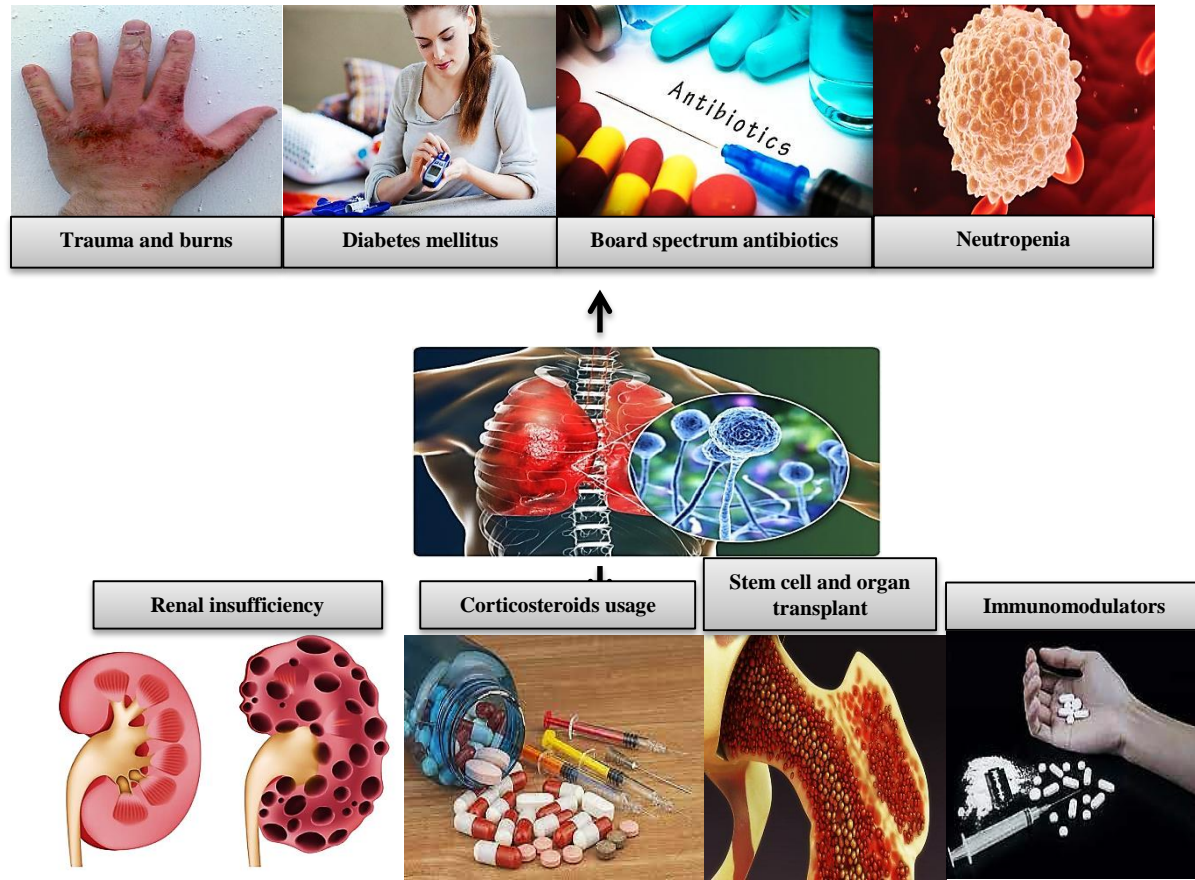


Fig. 1. Influence of underlying conditions on the susceptibility to and progression of mucormycosis [7]. This figure illustrates the accelerated spread of fungal infections in individuals with predisposing factors, highlighting the critical role of underlying diseases in the development and severity of mucormycosis.

COVID-19 and mucormycosis

To provide a summary of the clinical presentation and outcomes of mucormycosis in patients with COVID-19, we have collated data from relevant studies in Table 1.

The immune response to SARS-CoV-2 infection is characterized by a complex interplay of pro-inflammatory and anti-inflammatory signaling, the magnitude and duration of which can vary significantly depending on disease severity. In severe COVID-19 cases, a cytokine storm often occurs, marked by significantly elevated

levels of pro-inflammatory cytokines, including IL-6, IL-1 β , IFN- γ , MCP-1, CXCL10, and TNF- α [23]. While IL-4 and IL-10 can have anti-inflammatory effects, their dysregulation in the context of a cytokine storm can contribute to immunopathology. Notably, elevated TNF- α levels are associated with severe lung inflammation and increased mortality risk, highlighting the critical role of cytokine dysregulation in COVID-19 pathogenesis. Although mild cases typically exhibit a less pronounced inflammatory response, some degree of immune

dysregulation, including lymphocytopenia and alterations in cytokine levels, can still occur [24].

The administration of corticosteroids, often necessary to manage hyperinflammation in severe COVID-19, can further exacerbate immune dysfunction. Corticosteroids can lead to a decline in immune function and can also contribute to increased blood glucose levels, both in diabetic and non-diabetic individuals [25, 26]. This effect on glucose metabolism is particularly concerning, as immunocompromise and hyperglycemia are established risk factors for mucormycosis. Individuals with compromised immune systems are at increased risk of developing mucormycosis, a trend reflected in the higher incidence rates observed in this population (Fig. 2, which depicts the relationship between immune status and mucormycosis risk). In the context of COVID-19, iron metabolism has emerged as a potential factor influencing mucormycosis susceptibility and severity. Elevated levels of circulating iron, often observed in COVID-19 patients, can provide a more favorable environment for Mucorales growth, potentially increasing the risk of infection [23].

Mucorales exhibit a high dependence on iron for growth and virulence, a characteristic that has prompted investigations into iron metabolism as a therapeutic target. Studies suggest that disrupting iron uptake by these fungal pathogens could be a promising therapeutic approach. For example, experimental evaluations have explored the use of iron chelators in mucormycosis treatment, with deferasirox demonstrating success in at least one case of rhinocerebral mucormycosis. Moreover, deferoxamine has shown potential in mitigating the COVID-19-related inflammatory response in diabetic patients. While further research is needed to establish their efficacy in clinical settings, these findings suggest that iron chelators, particularly deferasirox, which is FDA-approved and clinically used in Europe and India, warrant further investigation as a potential adjunctive treatment strategy for mucormycosis [27].

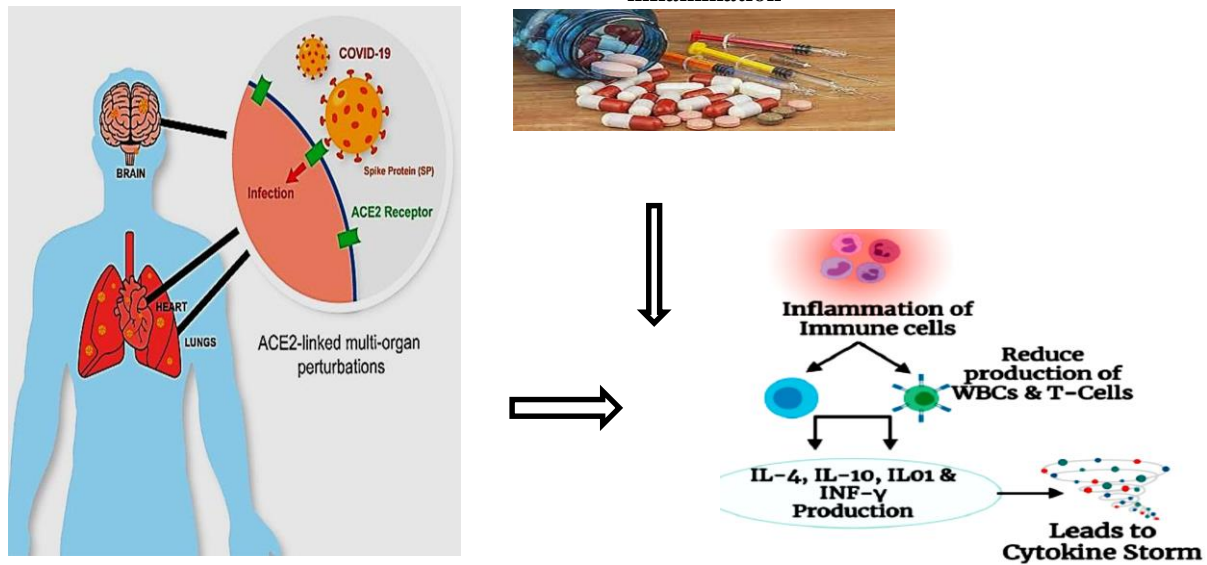
In addition to iron dysregulation and immune suppression, certain medical interventions commonly employed in the management of COVID-19 can inadvertently increase the risk of mucormycosis. For instance, patients with COVID-19 often require oxygen therapy, which, if not carefully maintained, can inadvertently increase the risk of mucormycosis. Contaminated oxygen equipment and water sources can serve as a source of fungal spores, potentially leading to infection, particularly in patients with compromised respiratory tracts [28, 29]. This underscores the importance of vigilant infection control measures, including strict sterilization protocols for medical equipment, to minimize the risk of mucormycosis transmission in healthcare settings.

The clinical presentation of mucormycosis in patients with COVID-19 can vary depending on the site of infection and the stage of disease. However, a hallmark of mucormycosis is its rapid and aggressive progression, often leading to life-threatening complications if not promptly diagnosed and treated. Initial symptoms often manifest in the rhino-orbital region, the most common site of infection in CAM. These early signs may include unilateral facial pain, headache, nasal congestion or discharge, periorbital swelling, erythema, and blurring of vision. Systemic symptoms, such as fever, malaise, and weight loss, are also common. As the infection progresses, patients may develop more severe and organ-specific manifestations, including: rhino-orbital/Rhino-orbitocerebral (necrotic lesions in the nasal cavity or palate, proptosis (protrusion of the eyeball), cranial nerve palsies leading to facial drooping or difficulty speaking, altered mental status, seizures; pulmonary (shortness of breath, chest pain, cough, and coughing up blood); and gastrointestinal (abdominal pain, nausea, vomiting, and bloody stools). Early recognition of these signs and symptoms is crucial for prompt diagnosis and timely initiation of treatment [30].

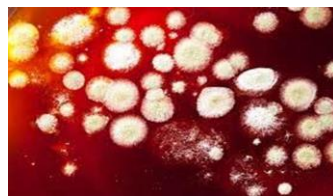
Obesity has emerged as an independent risk factor for mucormycosis in the setting of COVID-19, even in the absence of diabetes. This increased risk may be attributed, in part, to the dysregulated release of adipokines from adipose tissue in obese individuals. Adipokines can disrupt glucose metabolism and immune function, potentially creating a more favorable environment for mucormycosis development. Furthermore, obesity is often associated with a chronic low-grade inflammatory state, characterized by elevated levels of circulating pro-inflammatory cytokines. This underlying inflammation, when exacerbated by COVID-19 infection, can further impair immune responses and increase susceptibility to opportunistic infections. Moreover, in obese individuals with recent COVID-19 infection, the excess adipose tissue can contribute to increased oxidative stress, characterized by the excessive production of reactive oxygen species (ROS) [26]. This heightened oxidative stress, along with impaired macrophage function and altered T cell responses, can further compromise immune defenses, potentially increasing susceptibility to opportunistic infections like mucormycosis [28].

Mucormycosis, particularly in the setting of COVID-19, is associated with significant morbidity and mortality. Mortality rates for CAM in patients with a history of underlying conditions have been reported to range from 38% to 80% [28, 29], highlighting the severity of this opportunistic infection.

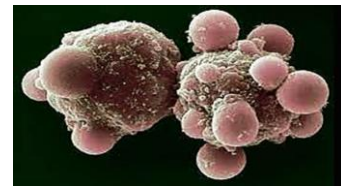
Requirement for steroids, immunosuppressants and antibiotics for reducing inflammation



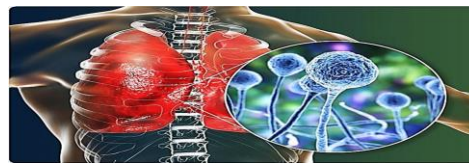
Immune dysregulation



Unable to fight fungal infection



Cell damage to apoptosis



Mucormycosis

Fig. 2. Immunopathological consequences of COVID-19 and their contribution to mucormycosis susceptibility [24]. The excessive production of pro-inflammatory cytokines in critically ill patients can lead to immune suppression, exacerbating the severity of mucormycosis.

Studies have observed a clear temporal association between COVID-19 and the development of mucormycosis. While some individuals exhibit symptoms of COVID-19 preceding the onset of fungal infection, others experience a delayed onset, with mucormycosis

emerging after apparent recovery from COVID-19 [11, 31-32]. This delayed onset underscores the importance of considering mucormycosis as a potential complication even in individuals who have seemingly recovered from COVID-19, particularly those with persistent risk factors such as obesity, diabetes, and immunosuppression [26].

Table 1. Recent studies on COVID-19 cases associated with mucormycosis, highlighting the emergence of this fungal infection as a significant complication in the pandemic.

Case no.	Subject	Summary of results	Place of Study/Methodology	Ref
1	Multicenter Epidemiologic Study of Coronavirus Disease-Associated Mucormycosis	Factors such as older age and rhino-orbito-cerebral involvement were associated with increased mortality. Early initiation of antifungal treatment improved survival rates in individuals with mucormycosis. The COVID-19 pandemic has led to a notable increase in the incidence of mucormycosis, particularly in patients with underlying diseases.	India: Retrospective analysis of data from 295 consecutive mucormycosis cases diagnosed at 16 participating centers.	[33]
2	COVID-19-associated rhino-orbital-cerebral mucormycosis in 2826 patients	At the final follow-up, the mortality rate was 14%. COVID-19-related hypoxemia and improper glucocorticoid use were independently associated with an increased risk of developing mucormycosis.	India: Among 287 mucormycosis patients identified, 187 (65.2%) had COVID-19-associated mucormycosis. The prevalence of COVID-19-associated mucormycosis was 0.27% among hospitalized COVID-19 patients.	[34]
3	COVID-19-associated mucormycosis	In contrast to the high incidence of CAM observed in India, COVID-19-associated mucormycosis was less common in Germany, primarily reported in patients with underlying diseases such as diabetes or immune system disorders or in those who developed severe COVID-19 requiring ICU admission. Notably, mortality rates were higher in Germany compared to India, likely due to differences in patient characteristics and healthcare access. As of July 20, 2021, India and its neighboring countries reported 45,432 confirmed cases of mucormycosis, with 4,252 deaths attributed to this fungal infection. Notably, approximately 85% of mucormycosis cases occurred in patients with COVID-19, and 65% occurred in individuals with diabetes, highlighting the significant overlap between these conditions. The authors emphasize the importance of implementing preventive measures to mitigate the risk of mucormycosis in Nepal and other Asiatic nations, drawing lessons from the outbreak experienced in neighboring India. The authors describe the clinical features, management, and outcomes of 99 COVID-19-associated mucormycosis cases reported globally up to May 14, 2021. They highlight the high morbidity and mortality associated with CAM, attributing the high long-term morbidity rate (100%) and mortality rate (37.5%) to factors such as late diagnosis, disease severity, and limitations in healthcare access.	Germany: Retrospective analysis of 13 COVID-19-associated mucormycosis cases diagnosed at six tertiary referral hospitals between March 2020 and June 2021.	[35]
4	Delta variant and black fungal invasion		India and its neighboring countries	[36]
5	Mucormycosis and COVID-19 an epidemic in a pandemic?		Nepal and other Asiatic nations	[37]
6	Black fungus, the darker side of COVID-19		Global case reports/series of COVID-19-associated mucormycosis (n=99) reported up to May 14, 2021, with cases primarily from the USA (10%), India (73%), and Egypt (6%).	[38]
7	Imaging of COVID-19-associated craniofacial mucormycosis	The authors emphasize the crucial role of imaging in the early diagnosis and management of COVID-19-associated craniofacial mucormycosis. They highlight the importance of a high index of suspicion among radiologists to facilitate prompt diagnosis and timely initiation of antifungal therapy, which can limit morbidity and mortality. The authors recommend contrast-enhanced MRI with complementary plain CT as the imaging techniques of choice	India	[8]

8	The responsible factors for the COVID-associate mucormycosis outbreak	This study investigates the factors contributing to the COVID-19-associated mucormycosis outbreak in India. The authors emphasize the need for a multidisciplinary approach to expedite surgeries in patients with severe fungal infections and COVID-19. They highlight the importance of stringent infection control measures, including the proper use of personal protective equipment, to prevent nosocomial transmission. Additionally, they underscore the need to manage iron metabolism in severely ill COVID-19 patients and ensure adequate ventilation in hospital areas with a high density of COVID-19 cases.	India	[39]
9	Is Mucormycosis an inevitable complication of COVID-19?	This study explores the potential link between antihyperglycemic drugs, weakened immune systems, and the risk of mucormycosis in COVID-19 patients. The authors stress the need to consider this potential association and carefully manage blood glucose levels in individuals with COVID-19, particularly those receiving immunosuppressive therapy.	India	[40]
10	COVID-19-associated mucormycosis	This study highlights the high mortality rate associated with COVID-19-associated mucormycosis, even with clinical and surgical interventions. The authors emphasize the importance of adhering to clinical guidelines for the appropriate use of antibiotics in COVID-19 management to minimize the risk of secondary fungal infections. They also underscore the need for a multidisciplinary approach to address the factors contributing to mucormycosis development in COVID-19 patients.	Turkey	[41]
11	A deadly black fungus infection among COVID-19 patients	This study emphasizes the importance of considering a patient's medical history when managing COVID-19, particularly for individuals with risk factors for mucormycosis, such as organ transplantation, liver cirrhosis, and neutropenia. The authors highlight early detection, surgical debridement of infected tissue, and antifungal therapy as crucial steps in managing this invasive fungal infection.	India	[31]
12	Mucormycosis in the COVID-19 pandemic	This study raises concerns about the potential emergence of antifungal resistance due to the widespread use of azithromycin (an antibiotic) and amphotericin B (an antifungal) in patients with COVID-19. The authors emphasize the need for antimicrobial stewardship to minimize the development and spread of drug-resistant pathogens.	India	[25]
13	Mucormycosis (Zygomycosis) among COVID-19 patients	This study highlights the use of amphotericin B as the most common antifungal agent in managing COVID-19-associated mucormycosis. The authors report that approximately 40% of cases require surgical intervention to control the infection. They emphasize the importance of monitoring for potential side effects of antifungal therapy, including electrolyte disturbances.	-	[32]

14	A perspective on the coronavirus disease (COVID-19)-associated rhino-orbital mucormycosis epidemic	This study provides insights into the rhino-orbital mucormycosis epidemic in the context of the COVID-19 pandemic in India. The authors suggest that the use of broad-spectrum antibiotics and prophylactic antifungals, while potentially life-saving in some COVID-19 patients, can disrupt the delicate balance of the sinonasal microbiome, potentially increasing the risk of opportunistic infections like mucormycosis.	India	[42]
15	COVID-19 associated mucormycosis: from diagnostic challenges to management	This study discusses the diagnostic and management challenges associated with COVID-19-associated mucormycosis in Pakistan. The authors highlight the emergence of mucormycosis as a significant problem in individuals recovering from COVID-19, emphasizing the need for continued vigilance and timely diagnosis even after the acute phase of COVID-19 has resolved.	Pakistan	[43]
16	Fatal strokes in patients with rhino-orbito-cerebral mucormycosis and associated vasculopathy	This study investigates the occurrence of fatal strokes in patients diagnosed with rhino-orbito-cerebral mucormycosis. The authors highlight the aggressive nature of this infection and its potential to invade blood vessels, leading to life-threatening complications. They recommend a combination of early and aggressive surgical debridement, ocular exenteration (removal of the eye and surrounding tissues), systemic and local amphotericin B therapy, and decompression craniotomy to improve outcomes in these critically ill patients.	Taiwan: Questionnaire survey	[44]
17	SARS-CoV-2, uncontrolled diabetes and corticosteroids-An unholy trinity in invasive fungal infections of the maxillofacial region?	This study highlights the increased incidence of angioinvasive maxillofacial fungal infections, including mucormycosis, in diabetic patients treated for COVID-19, particularly those receiving corticosteroid therapy. The authors emphasize the need for heightened awareness and early diagnosis of these infections in this high-risk population.	India: Retrospective analysis of patients who underwent MRI, computed tomography (CT) scan, and potassium hydroxide (KOH) mount examination.	[45]
18	Head and neck reconstruction during the COVID-19 pandemic	This study discusses the challenges and considerations for head and neck reconstruction surgery during the COVID-19 pandemic. While the study does not specifically focus on mucormycosis, it highlights the broader impact of the pandemic on surgical practices and the need to balance infection control measures with timely and appropriate surgical care.	International study/Review. Diagnostic methods included matrix-assisted laser desorption ionization time-of-flight mass spectrometry (MALDI-TOF MS), CT scans, and pathological examination.	[46]
19	<i>Rhizopus azygosporus</i> pneumonia following COVID-19	This case report describes a case of <i>Rhizopus azygosporus</i> pneumonia in a patient recovering from COVID-19. The authors highlight the potential for severe fungal infections, even in individuals without typical risk factors, and suggest that the use of immunosuppressive medications in the management of COVID-19 might contribute to the risk of mucormycosis. They emphasize the need for vigilance and early suspicion in hospitalized COVID-19 patients, particularly those receiving immunosuppressive therapy.	USA: Case report. Diagnostic methods included polymerase chain reaction (PCR) testing and chest X-ray.	[47]

20	Rhino-orbital mucormycosis associated with COVID-19	This study reports on a case of rhino-orbital mucormycosis in a patient with COVID-19. The authors emphasize the importance of early diagnosis and treatment to improve outcomes and reduce the risk of complications. They also call for a re-evaluation of antibiotic use in COVID-19 patients, particularly in cases where there is no clear evidence of bacterial infection, to minimize the risk of disrupting the microbiome and predisposing individuals to opportunistic fungal infections.	India: Case report. Diagnostic methods included reverse-transcriptase polymerase chain reaction (RT-PCR) and chest CT scan.	[48]
21	Mucormycosis with orbital compartment syndrome in a patient with COVID-19	This case report describes the development of mucormycosis with orbital compartment syndrome, a serious complication, in a patient with COVID-19 and uncontrolled diabetes. The authors emphasize the importance of recognizing and managing both infections promptly to prevent vision-threatening complications.	Case report. Diagnostic imaging included CT of the head, face, and orbits; MRI of the brain; and chest X-ray.	[49]
22	Rhino-orbital mucormycosis in a patient with COVID-19	This case report presents the successful management of rhino-orbital mucormycosis in a critically ill patient with COVID-19. The authors highlight the importance of a multidisciplinary approach, emphasizing that improving the patient's respiratory status is paramount, even if it requires the use of corticosteroids, which can potentially exacerbate fungal infections.	USA: Case report. Diagnostic methods included sinus histopathology, MRI, and CT of the head.	[50]
23	Histopathological findings and viral tropism in patients with COVID-19	This study reports on the histopathological findings in patients who died from COVID-19. Notably, the authors describe several novel autopsy findings, including pancreatitis, pericarditis, adrenal micro-infarction, secondary disseminated mucormycosis, and brain microglial activation. They emphasize the need for further research to elucidate the role of these findings in the pathogenesis of COVID-19 and its complications.	UK: Retrospective analysis of autopsy specimens. Diagnostic methods included histochemical analysis, immunohistochemical analysis, histopathological analysis, and RT-PCR.	[51]
24	Gastrointestinal Mucormycosis in a COVID-19 patient	This case report describes a case of gastrointestinal mucormycosis in a patient with COVID-19. The authors emphasize the importance of considering mucormycosis in the differential diagnosis of gastrointestinal symptoms in COVID-19 patients, particularly those with risk factors. They suggest that preemptive antifungal therapy should be considered in high-risk individuals with clinical features suggestive of mucormycosis.	Brazil: Case report. Diagnostic methods included esophagogastroduodenoscopy, chest computed tomography, hematoxylin and eosin (H&E) staining, and abdominal CT scan.	[52]
25	Influenza-associated mucormycosis versus COVID-19-associated mucormycosis	This study compares the clinical characteristics and outcomes of influenza-associated mucormycosis and COVID-19-associated mucormycosis. The authors report that patients with influenza-associated mucormycosis had a better prognosis, which they attribute to earlier diagnosis, localized infection, better glycemic control, and aggressive treatment with a combination of antifungal therapy and surgical debridement.	Iran: Retrospective analysis of patients with influenza-associated mucormycosis and COVID-19-associated mucormycosis. Diagnostic methods included H&E staining, RT-PCR, CT scan, and MRI.	[53]
26	COVID-19 patients co-infected with rhino-orbital mucormycosis	This case series describes the clinical presentation, imaging findings, and management of six patients with COVID-19 and rhino-orbital mucormycosis. The authors highlight the characteristic clinical features, such as complete eyelid ptosis, restricted eye movements, and loss of light perception, as well as the typical imaging findings, such as ethmoid sinus opacity and mucosal thickening on MRI. They emphasize the importance of early diagnosis and prompt initiation of treatment to improve outcomes.	Iran: Case series. Diagnostic methods included T1-weighted MRI, H&E staining, and contrast-enhanced MRI.	[54]

Given the increased risk of mucormycosis in the context of COVID-19, patient education is paramount, particularly for those with predisposing factors like diabetes, immunosuppression (*e.g.*, due to corticosteroid therapy), or other comorbidities. Effective patient education is an essential component of a comprehensive strategy to mitigate the risk of CAM.

Education should be provided throughout the course of COVID-19 care, including during hospitalization and at the time of discharge. Key messages should include: (1) Information on recognizing early warning signs of mucormycosis: Patients and their families should be educated on the common presenting symptoms of mucormycosis, such as nasal discharge or congestion, facial pain or swelling, headache, fever, vision changes (*e.g.*, blurring, double vision, loss of vision), and skin lesions (*e.g.*, redness, swelling, warmth, pain); (2) Guidance on preventive measures: Patients should be advised on preventive measures, including meticulous blood glucose control (for individuals with diabetes), proper hygiene practices (*e.g.*, frequent handwashing, avoiding contact with contaminated materials), and the potential benefits and risks of nasal saline rinses; and (3) The importance of prompt medical attention if any suggestive symptoms arise: Patients should be strongly advised to seek immediate medical attention if they develop any signs or symptoms suggestive of mucormycosis. Early diagnosis and treatment are crucial for improving outcomes in this potentially life-threatening infection [52-55].

Mucormycosis can manifest in various forms, with rhino-orbital-cerebral mucormycosis being the most common presentation in CAM, particularly in individuals with compromised immune systems. The pathogenesis of mucormycosis is multifactorial, involving a complex interplay of host, viral, and environmental factors. While the exact pathogenesis of mucormycosis is complex and not fully elucidated, several factors contribute to its development, including: (1) host factors, such as uncontrolled diabetes (Hyperglycemia and ketoacidosis create an environment conducive to fungal growth, and impaired immune function further increases susceptibility); immunosuppression resulting from underlying conditions (*e.g.*, HIV/AIDS, hematological malignancies), medications (*e.g.*, corticosteroids, chemotherapy), or medical procedures (*e.g.*, organ transplantation); Iron overload (Mucorales require iron for growth and virulence, and elevated serum iron levels, often observed in COVID-19, can promote fungal proliferation); and other comorbidities (malnutrition, renal insufficiency, and deferoxamine therapy (an iron chelator) have also been associated with an increased risk of mucormycosis), (2) viral factors, such as the immune dysregulation and hyperinflammation (COVID-19 can disrupt immune homeostasis, leading to impaired immune cell function and an exaggerated inflammatory response, both of which can increase susceptibility to opportunistic

infections), and (3) environmental factors, including exposure to Mucorales spores (these spores are ubiquitous in the environment, and inhalation is the primary route of infection); and hospital-acquired infections (contaminated medical equipment, water sources, and building materials can serve as reservoirs for Mucorales, posing a risk to hospitalized patients, particularly those in intensive care units). Understanding the interplay of these factors is crucial for developing effective strategies to prevent and manage mucormycosis, especially in the context of the COVID-19 pandemic [40, 56].

The COVID-19 pandemic has highlighted the importance of environmental monitoring and infection control measures in healthcare settings. For example, investigations into the surge of mucormycosis cases in India, which experienced a particularly severe outbreak, pointed to a potential role of contaminated oxygen delivery systems and healthcare-associated transmission. Furthermore, the widespread use of corticosteroids and other immunosuppressive therapies to manage severe COVID-19, along with the high prevalence of diabetes in India, likely contributed to the increased incidence of mucormycosis in this region [40, 56]. These observations underscore the need for heightened vigilance, stringent infection control protocols, and a comprehensive understanding of the multifaceted interplay between host, viral, and environmental factors in driving mucormycosis outbreaks.

Challenges and side effects

Mucormycosis, particularly when occurring in the setting of COVID-19, is associated with significant morbidity and mortality. Studies have reported varying mortality rates in patients co-infected with mucormycosis and COVID-19, depending on factors such as the form of mucormycosis, the severity of COVID-19, and the presence of underlying comorbidities. A significant number of COVID-19-associated mucormycosis cases have been reported both during hospitalization and following hospital discharge. For instance, data from India indicate that a substantial proportion of COVID-19 patients who develop mucormycosis present with signs and symptoms within 14 to 28 days of being discharged from the hospital [41, 57]. This delayed onset highlights the importance of ongoing vigilance and follow-up care for COVID-19 patients, even after they have been discharged, as they may remain at risk for developing opportunistic infections like mucormycosis.

Several factors can significantly influence the progression of mucormycosis and increase the risk of adverse outcomes. Individuals with underlying conditions, such as uncontrolled diabetes, hematological malignancies, solid organ transplantation, and prolonged immunosuppressive therapy, are particularly vulnerable. These conditions can impair the immune system's ability to effectively control fungal growth and dissemination, leading to more rapid disease progression and a higher

likelihood of complications. Moreover, factors related to healthcare delivery, such as limited access to specialized care, delays in diagnosis and treatment initiation, and the potential for healthcare-associated infections due to contaminated medical equipment or inadequate infection control practices, can exacerbate the challenges of managing mucormycosis, especially in resource-limited settings [51].

Mucormycosis can affect various anatomical sites, including the sinuses, lungs, skin, brain, and eyes. The route of infection often depends on the specific form of mucormycosis and the host's underlying susceptibility. For instance, in rhino-orbital-cerebral mucormycosis, a common presentation, the fungus often invades from the ethmoidal sinus, penetrating the thin bony lamina papyracea to enter the orbit. From there, it can spread to the maxillary sinus and potentially penetrate the orbital apex, gaining access to the brain [51]. This contiguous spread is facilitated by the proximity of these structures and the rich vascular supply of the region, which can be further compromised in individuals with poorly controlled diabetes or other conditions affecting blood vessel integrity [58].

Cerebral dissemination of mucormycosis is a serious complication that can lead to meningoencephalitis, a severe infection of the brain and surrounding tissues. Meningoencephalitis can manifest with a range of neurological complications, including cognitive impairment, memory loss, delirium, altered mental status, seizures, and coma. While any form of mucormycosis can potentially disseminate to the brain, the frequency of different infection sites can vary depending on the patient population and the underlying risk factors. For instance, one study found the most frequent involvement to be the sinuses (39%), followed by the lungs (24%), skin (19%), brain (9%), and gastrointestinal tract (7%) [4].

Diagnosis

Diagnosing mucormycosis relies on a multifaceted approach, as relying solely on fungal culture results from clinical samples (obtained from living patients and autopsies) has shown limitations. Studies have revealed that fungal cultures from COVID-19 patients with mucormycosis can yield false-negative results, highlighting that this method alone lacks the necessary sensitivity for rapid and reliable diagnosis of this aggressive infection [8].

Direct microscopic examination of clinical specimens, such as tissue biopsies or fluids, remains a cornerstone of mucormycosis diagnosis. This can be achieved through techniques like potassium hydroxide (KOH) and calcofluor white staining, which help visualize the characteristic broad, non-septate hyphae of mucormycetes. In addition to direct visualization, molecular detection techniques have emerged as valuable tools for rapid and accurate diagnosis of fungal infections, including mucormycosis. These methods are particularly

useful for identifying fungal pathogens isolated from clinical specimens and can provide results even when direct microscopy is inconclusive. Molecular targets commonly employed for mucormycosis diagnosis include genes encoding ribosomal DNA proteins and the internal transcribed spacer region of fungal DNA. Along with laboratory techniques, imaging plays a crucial role in assessing the extent of infection. Computed tomography (CT) scans are generally preferred over magnetic resonance imaging (MRI) for visualizing mucormycosis, especially in cases of bone damage, paranasal sinus involvement, and orbital compromise [58].

While both computed tomography (CT) and magnetic resonance imaging (MRI) can aid in diagnosing mucormycosis, they offer distinct advantages depending on the clinical scenario. CT, being more widely available and cost-effective than MRI, is often the initial imaging modality employed. CT excels in detecting bony abnormalities associated with mucormycosis, such as erosion, destruction, and periosteal thickening, particularly in the sinuses. Additionally, chest CT is more sensitive than conventional radiography for detecting pulmonary involvement. On the other hand, MRI boasts superior soft tissue contrast resolution compared to CT, making it valuable for evaluating suspected intracranial extension of mucormycosis or differentiating between inflammation and fungal invasion within soft tissues [59, 60]. Therefore, the choice between CT and MRI should be individualized based on factors such as the suspected site of infection, patient characteristics, and the potential risks and benefits of each modality, including radiation exposure from CT [61].

Beyond the aforementioned diagnostic tools, a high index of clinical suspicion is crucial for timely diagnosis of mucormycosis, especially in patients with COVID-19 who present with suggestive symptoms and risk factors. These risk factors include steroid use, diabetes, iron overload, excessive antibiotic use, and hypoxia [41]. The high mortality rate associated with COVID-19-associated mucormycosis, even with medical and surgical interventions, highlights the need for a multidisciplinary approach to effectively manage and mitigate outbreaks [41]. Given the aggressive nature of mucormycosis, a prompt diagnosis is essential. Tissue biopsy remains the gold standard for definitive diagnosis, allowing for histopathological examination and fungal culture. While routine blood tests may reveal nonspecific markers of inflammation or organ dysfunction, they are not specific for mucormycosis. Although antigen and antibody testing and molecular methods (DNA/RNA detection) are emerging diagnostic tools, their sensitivity and specificity for mucormycosis are still under investigation. Radiological imaging, particularly CT and MRI, plays a crucial role in assessing the extent and location of the infection [62, 63].

Treatments

Managing mucormycosis, a potentially life-threatening infection, requires a swift and multidisciplinary approach. Upon suspicion, treatment often involves both surgical and medical interventions. Surgical management typically entails debridement of necrotic tissue, which often requiring multiple procedures, and may involve extensive resection of affected areas, including sinus cavities or orbital exenteration. Medical management centers around antifungal therapy, with liposomal amphotericin B being the preferred first-line agent. In addition to amphotericin B, other antifungals, such as posaconazole or isavuconazole, may be used as alternative or salvage therapies, often in combination with amphotericin B [24].

Given the potential for multi-organ involvement and the complexity of managing both COVID-19 and mucormycosis, a multidisciplinary team is paramount for optimal patient care. This team often includes infectious disease specialists, otorhinolaryngologists, plastic and reconstructive surgeons, ophthalmologists, endocrinologists, and critical care specialists. Additionally, neurologists, neurosurgeons, nephrologists, and pharmacotherapists may be involved depending on the extent and location of the infection. While the specific treatment costs for mucormycosis vary widely based on factors such as geographic location, hospital setting, and individual patient needs, it is important to note that managing this infection often involves prolonged hospitalization, complex surgical procedures, and long-term antifungal therapy. Consequently, this underscores the substantial economic burden associated with mucormycosis, further emphasizing the importance of early diagnosis and effective management strategies [64, 65].

Surgical treatment

Surgical treatment of mucormycosis typically involves aggressive debridement of necrotic and infected tissues. This may include areas such as the nose, sinuses, palate, pterygopalatine space, orbit, and cranium, depending on the extent of disease. In advanced cases involving extensive orbital apex necrosis and irreversible vision loss, orbital exenteration may be considered. However, due to its invasive nature and the potential for significant aesthetic and functional complications, this procedure is generally reserved as a last resort [43]. The decision to proceed with orbital exenteration, or any surgical intervention, should be carefully evaluated in light of the potential benefits, considering factors such as the extent of disease, the likelihood of achieving disease control, and the overall prognosis for survival [44].

Medical treatment

Antifungal therapy forms the cornerstone of medical management for mucormycosis. Amphotericin B, posaconazole, and isavuconazole are the agents with proven efficacy against mucormycetes. While

liposomal amphotericin B is generally preferred due to its improved safety profile, the choice between formulations and dosages should be individualized based on factors such as the site of infection, disease severity, and renal function. For instance, in patients with cerebral mucormycosis, liposomal amphotericin B is typically initiated at a dosage of 5-10 mg/kg/day [66]. It is important to note that other azoles like fluconazole and voriconazole, as well as echinocandins like caspofungin, lack activity against mucormycetes and are ineffective for treatment. Although amphotericin B remains the mainstay of therapy, posaconazole may be used as salvage therapy in cases of refractory infection or as step-down therapy following initial improvement with amphotericin B [67]. Treatment duration typically ranges from 4-6 weeks to several months, depending on the clinical response and radiological resolution of the infection [67].

In cases of suspected mucormycosis, particularly in critically ill patients, antifungal therapy should be initiated promptly, even before obtaining microbiological confirmation. This empirical approach is crucial given the rapid progression of the disease and the potential delays in obtaining definitive diagnostic results. Although every effort should be made to secure a definitive diagnosis through histopathology or culture, treatment should not be withheld while awaiting these results [67]. However, if a diagnosis of mucormycosis is not confirmed within a reasonable timeframe, typically within 72 hours, the risks and benefits of continuing antifungal therapy should be carefully reassessed, taking into account the patient's clinical course, response to treatment, and the likelihood of alternative diagnoses [66].

CONCLUSION

This review underscores the heightened risk of mucormycosis among COVID-19 patients, primarily driven by factors like immunosuppressive therapy, underlying comorbidities, and potential healthcare-associated exposures. Mitigating this risk demands a multipronged approach incorporating stringent infection control protocols (*e.g.*, meticulous hygiene, appropriate disinfection), judicious use of corticosteroids, and heightened awareness among both healthcare providers and patients. Early diagnosis, facilitated by a high index of suspicion and prompt diagnostic testing, is crucial for improving individual patient outcomes. In addition to a multidisciplinary approach to management, further research is urgently needed to optimize treatment strategies, particularly regarding adjunctive therapies, antifungal stewardship, and long-term management of post-mucormycosis sequelae. Furthermore, investigating the long-term risks and potential for recurrence in COVID-19 survivors who developed mucormycosis is paramount.

While both medical and surgical advancements have improved the management of mucormycosis, significant challenges remain. Surgical debridement, while a cornerstone of therapy, particularly for localized infections, may not be feasible or sufficient for all cases, such as those involving extensive pulmonary or central nervous system involvement. Furthermore, this underscores the critical need for effective antifungal agents and adjunctive therapies, as well as innovative approaches to improve drug delivery to challenging anatomical sites. Early diagnosis, driven by heightened clinical suspicion and timely diagnostics, remains paramount for improving outcomes. Therefore, further research should focus on optimizing antifungal regimens, developing novel therapeutic strategies, and elucidating the long-term sequelae of mucormycosis, particularly in the context of COVID-19. Moreover, beyond direct medical management, addressing broader public health issues, such as promoting the rational use of medications and discouraging self-medication practices, is crucial to minimize inappropriate antifungal use and mitigate the emergence of antifungal resistance.

ACKNOWLEDGEMENT

The authors gratefully acknowledge the financial and technical support provided by the Deputy of Research and Technology at Mazandaran University of Medical Sciences. This support was instrumental for the completion of this review.

CONFLICTS OF INTEREST

The authors declare that there are no conflicts of interest associated with this manuscript.

REFERENCES

- Petrikkos G, Skiada A, Lortholary O, Roilides E, Walsh TJ, Kontoyiannis DP. Epidemiology and clinical manifestations of mucormycosis. *Clin Infect Dis*. 2012; 54 (1): 23-34.
- Singh A., Singh R, Joshi SR, Misra, A. Mucormycosis in COVID-19: a systematic review of cases reported worldwide and in India. *Diabetes Metab Syndr*. 2021; 15 (4): 102146.
- Saberi Hasanabadi P, Ataei R. A review on current side effects of used drugs during treatment of patients with COVID-19. *Pharm Biomed Res*. 2021; 7 (4): 251-60.
- Roden MM, Zaoutis TE, Buchanan WL. Epidemiology and outcome of mucormycosis: a review of 929 reported cases. *Clin Infect Dis*. 2005; 41: 634-53.
- Kontoyiannis DP. Decrease in the number of reported cases of zygomycosis among patients with diabetes mellitus: a hypothesis. *Clin Infect Dis*. 2007; 44 (8): 1089-90.
- Bouza, E, Munoz P, Guinea J. Mucormycosis: an emerging disease? *Clin Microbiol Infect*. 2006; 12 (7): 7-23.
- Gomes MZ, Lewis RE, Kontoyiannis DP. Mucormycosis caused by unusual mucormycetes, non-*Rhizopus*, *Mucor*,

and *Lichtheimia* species. *Clin Microbiol Rev*. 2011; 24 (2): 411-45.

- Sanghvi D, Kale H. Imaging of COVID-19-associated craniofacial mucormycosis: a black and white review of the "black fungus". *Clin Radiol*. 2021; 76 (11): 812-9.
- Malhotra HS, Gupta P, Mehrotra D, Dandu H, Kohli N, Verma V, et al. COVID-19 associated mucormycosis: Staging and management recommendations (Report of a multi-disciplinary expert committee). *J Oral Biol. Craniofac*. 2021; 11(4): 569-80.
- Sachdev SS, Chettiankandy TJ, Gaikwad R, Suryawanshi S, Yaduwanshi K. COVID-19 associated Mucormycosis: The call for dental practitioners. *Clin Dent*. 2021; 15 (6): 19-23.
- Selarka L, Sharma S, Saini D, Sharma S, Batra A, Waghmare VT, et al. Mucormycosis and COVID-19: An epidemic within a pandemic in India. *Mycoses*. 2021; 64 (10): 1253-60.
- Dubey S, Mukherjee D, Sarkar P, Mukhopadhyay P, Barman D, Bandopadhyay M, et al. COVID-19 associated rhino-orbital-cerebral mucormycosis: An observational study from Eastern India, with special emphasis on neurological spectrum. *Diabetes Metab Syndr*. 2021; 15 (5): 102267.
- Al-Ajam MR, Bizri AR, Mokhbat J, Weedon J, Lutwick L. Mucormycosis in the Eastern Mediterranean: a seasonal disease. *Epidemiol Infect*. 2006; 134 (2): 341-6.
- Talmi YP, Goldschmied-Reouven A, Bakon M, Barshack I, Wolf M, Horowitz Z, et al. Rhino-orbital and rhino-orbito-cerebral mucormycosis. *Otolaryngol Head Neck Surg*. 2002; 127 (1): 22-31.
- Sivagnanam S, Sengupta DJ, Hoogestraat D, Jain R, Stednick Z, Fredricks DN, et al. Seasonal clustering of sinopulmonary mucormycosis in patients with hematologic malignancies at a large comprehensive cancer center. *Antimicrob Resist Infect Control*. 2017; 6: 123.
- Chakrabarti A, Singh R. Mucormycosis in India: unique features. *Mycoses*. 2014; 57: 85-90.
- Jeong W, Keighley C, Wolfe R, Lee WL, Slavin MA, Kong DCM, et al. The epidemiology and clinical manifestations of mucormycosis: a systematic review and meta-analysis of case reports. *Clin Microbiol Infect*. 2019; 25 (1): 26-34.
- Muthu V, Rudramurthy SM, Chakrabarti A, Agarwal R. Epidemiology and pathophysiology of COVID-19-associated mucormycosis: India versus the rest of the world. *Mycopathologia*. 2021; 186 (6): 739-54.
- Skiada A, Pavleas I, Drogari-Apiranthitou M. Epidemiology and diagnosis of mucormycosis: an update. *J Fungi*. 2020; 6 (4): 265.
- Saberi-Hasanabadi P, Mohammadi H. COVID-19 Pandemic: Management and Challenges. *Pharm Biomed Res*. 2021; 7 (2): 67-78.
- Dolatabadi S, Ahmadi B, Rezaei-Matehkolaei A, Zarrinfar H, Skiada A, Mirhendi H, et al. Mucormycosis in Iran: A six-year retrospective experience. *J Mycol Med*. 2018; 28 (2): 269-73.
- Sharma A, Goel A. Mucormycosis: risk factors, diagnosis, treatments, and challenges during COVID-19 pandemic. *Folia Microbiol*. 2022; 67 (3): 363-87.

23. Llata E, Blossom DB, Khoury HJ, Rao CY, Wannemuehler KA, Noble-Wang J, et al. A cluster of mucormycosis infections in hematology patients: challenges in investigation and control of invasive mold infections in high-risk patient populations. *Diagn Microbiol Infect Dis.* 2011; 71 (1): 72-80.
24. Mahalaxmi I, Jayaramayya K, Venkatesan D, Subramaniam MD, Renu K, Vijayakumar P, et al. Mucormycosis: An opportunistic pathogen during COVID-19. *Environ Res.* 2021; 201: 111643.
25. Kumar M, Sarma DK, Shubham S, Kumawat M, Verma V, Singh B, et al. Mucormycosis in COVID-19 pandemic: Risk factors and linkages. *Curr Res Microb Sci.* 2021; 2: 100057.
26. Chauhan K, Soni D, Sarkar D, Karuna T, Sharma B, Singh S, et al. Mucormycosis after COVID-19 in a patient with diabetes. *Lancet.* 2021; 398 (10301): 10.
27. Naseef PP, Elayadeth-Meethal M, Salim KM, Anjana A, Muhas C, Vajid KA, et al. Therapeutic potential of induced iron depletion using iron chelators in Covid-19. *Saudi J Biol Sci.* 2022; 29 (4): 1947-56.
28. Khatri A, Chang KM, Berlinut I, Wallach F. Mucormycosis after Coronavirus disease 2019 infection in a heart transplant recipient—case report and review of literature. *J Mycol Med.* 2021; 101125.
29. Mishra N, Mutya VSS, Thomas A, Rai G, Reddy B, Mohanan AA, et al. A case series of invasive mucormycosis in patients with COVID-19 infection. *Int J Otorhinolaryngol Head Neck Surg.* 2021; 7 (5): 867-70.
30. Garg D, Muthu V, Sehgal IS, Ramachandran R, Kaur H, Bhalla A, et al. Coronavirus disease (COVID-19) associated mucormycosis (CAM): case report and systematic review of literature. *Mycopathologia.* 2021; 186 (2): 289-98.
31. Choudhary NK, Jain AK, Soni R, Gehlot N. Mucormycosis: A deadly black fungus infection among COVID-19 patients in India. *Clin Epidemiol Glob Health.* 2021; 100900.
32. Ramphul K, Verma R, Kumar N, Ramphul Y, Mejias S, Lohana P. Rising concerns of Mucormycosis (Zygomycosis) among COVID-19 patients; an analysis and review based on case reports in literature. *Acta Biomed.* 2021; 92 (4): e2021271.
33. Patel A, Agarwal R, Rudramurthy SM, Shevkani M, Xess I, Sharma R, et al. Multicenter epidemiologic study of coronavirus disease—associated mucormycosis. *India Emerg Infect Dis.* 2021; 27 (9): 2349-59.
34. Sen M, Honavar SG, Bansal R, Sengupta S, Rao R, Kim U, et al. Epidemiology, clinical profile, management, and outcome of COVID-19-associated rhino-orbital-cerebral mucormycosis in 2826 patients in India—Collaborative OPAI-IJO Study on Mucormycosis in COVID-19 (COSMIC), Report 1. *Indian J Ophthalmol.* 2021; 69 (7): 1670-92.
35. Seidel D, Simon M, Sprute R, Lubnow M, Evert K, Speer C, et al. Results from a national survey on COVID-19-associated mucormycosis in Germany: 13 patients from six tertiary hospitals. *Mycoses.* 2022; 65 (1): 103-9.
36. Bari MS, Hossain MJ, Akhter S, Emran TB. Delta variant and black fungal invasion: A bidirectional assault might worsen the massive second/third stream of COVID-19 outbreak in South-Asia. *Ethics Med Public Health.* 2021; 19: 100722.
37. Banerjee I, Robinson J, Asim M, Sathian B, Banerjee I. Mucormycosis and COVID-19 an epidemic in a pandemic? *Nepal J Epidemiol.* 2021; 11 (2): 1034-9.
38. Drissi C. Black fungus, the dark side of COVID-19. *J Neuroradiol.* 2021; 48 (5): 317-18.
39. Ravindra K, Ahlawat A. Five probable factors responsible for the COVID-associated mucormycosis outbreak in India. *Int J Infect Dis.* 2021; 112: 278-80.
40. Bhogireddy R, Krishnamurthy V, Pullaiah CP, Manohar S. Is Mucormycosis an inevitable complication of Covid-19 in India? *Braz J Infect Dis.* 2021; 25 (3): 101597.
41. Dilek A, Ozaras R, Ozkaya S, Sunbul M, Sen EI, Leblebicioğlu H. COVID-19-associated mucormycosis: Case report and systematic review. *Travel Med Infect Dis.* 2021; 102148.
42. Thakar A, Lal D. “Black fungus”: a perspective on the coronavirus disease 2019 (COVID-19)-associated rhino-orbital mucormycosis epidemic in India. *Int Forum Allergy Rhinol.* 2021; 11 (8): 1278-9.
43. Yasmin F, Najeeb H, Naeem A, Dapke K, Phadke R, Asghar MS, et al. COVID-19 associated mucormycosis: a systematic review from diagnostic challenges to management. *Diseases,* 2021; 9 (4): 65.
44. Thajeb P, Thajeb T, Dai D. Fatal strokes in patients with rhino-orbito-cerebral mucormycosis and associated vasculopathy. *Scand J Infect Dis.* 2004; 36 (9): 643-8.
45. Moorthy A, Gaikwad R, Krishna S, Hegde R, Tripathi KK, Kale PG, et al. SARS-CoV-2, Uncontrolled Diabetes and Corticosteroids—An Unholy Trinity in Invasive Fungal Infections of the Maxillofacial Region? A Retrospective, Multi-centric Analysis. *J Oral Maxillofac Surg.* 2021; 20 (3): 418-25.
46. Rashid HU, Rashid M, Khan N, Ansari SS, Bibi N. Taking a step down on the reconstruction ladder for head and neck reconstruction during the COVID-19 pandemic. *BMC Surg.* 2021; 21: 120.
47. Kanwar A, Jordan A, Olewiler S, Wehberg K, Cortes M, Jackson BR. A fatal case of *Rhizopus azygosporus* pneumonia following COVID-19. *J Fungi.* 2021; 7 (3): 174.
48. Mehta S, Pandey A. Rhino-orbital mucormycosis associated with COVID-19. *Cureus.* 2020; 12 (9): e10726.
49. Werthman-Ehrenreich A. Mucormycosis with orbital compartment syndrome in a patient with COVID-19. *Am J Emerg Med.* 2021; 42: 264-5.
50. Mekonnen ZK, Ashraf DC, Jankowski T, Grob SR, Vagefi MR, Kersten RC, et al. Acute invasive rhino-orbital mucormycosis in a patient with COVID-19-associated acute respiratory distress syndrome. *Ophthalmic Plast Reconstr Surg.* 2021; 37 (2): e40-e80.
51. Hanley B, Naresh KN, Roufosse C, Nicholson AG, Weir J, Cooke GS, et al. Histopathological findings and viral tropism in UK patients with severe fatal COVID-19: a post-mortem study. *Lancet Microbe.* 2020; 1 (6): 245-53.
52. do Monte Junior ES, Dos Santos MEL, Ribeiro IB, de Oliveira Luz G, Baba ER, Hirsch BS, et al. Rare and fatal

gastrointestinal mucormycosis (Zygomycosis) in a COVID-19 patient: a case report. *Clin Endosc.* 2020; 53 (6): 746-9.

53. Ahmadikia K, Hashemi SJ, Khodavaisy S, Getso MI, Alijani N, Badali H, et al. The double-edged sword of systemic corticosteroid therapy in viral pneumonia: A case report and comparative review of influenza-associated mucormycosis versus COVID-19 associated mucormycosis. *Mycoses.* 2020; 64 (8): 798-808.

54. Pakdel F, Ahmadikia K, Salehi M, Tabari A, Jafari R, Mehrparvar G, et al. Mucormycosis in patients with COVID-19: A cross-sectional descriptive multicentre study from Iran. *Mycoses.* 2021; 64 (10): 1238-52.

55. Saberi-Hasanabadi P, Farmad ME, Aboulfazli S, Kheirandish A, Ataie A, Boshtam S, et al. Azithromycin for COVID-19: Pharmacological Mechanisms, Challenges, and Prospects. *Acta Med Iran.* 2023; 61 (7): 378-86.

56. Maini A, Tomar G, Khanna D, Kini Y, Mehta H, Bhagyasree V. Sino-orbital mucormycosis in a COVID-19 patient: A case report. *Int J Surg Case Rep.* 2021; 82: 105957.

57. Martin H, Danila S, Agostinho C. The emergence of COVID-19 associated mucormycosis: Analysis of cases from 18 countries. *Lancet Microbe.* 2022; 3 (7): e543-e52.

58. Gamaletsou MN, Sipsas NV, Roilides E, Walsh TJ. Rhino-orbital-cerebral mucormycosis. *Curr Infect Dis Rep.* 2012; 14 (4): 423-34.

59. Desai SM, Gujarathi-Saraf A, Agarwal EA. Imaging findings using a combined MRI/CT protocol to identify the “entire iceberg” in post-COVID-19 mucormycosis presenting clinically as only “the tip”. *Clin Radiol.* 2021; 76 (10): 784.e27-784.e33.

60. Fazel R, Krumholz HM, Wang Y, Ross JS, Chen J, Ting HH, et al. Exposure to low-dose ionizing radiation from medical imaging procedures. *N Engl J Med.* 2009; 361 (9): 849-57.

61. Joshi AR, Muthe MM, Patankar SH, Athawale A, Achhapalia Y. CT and MRI findings of invasive mucormycosis in the setting of COVID-19: experience from a single center in India. *Am J Roentgenol.* 2021; 217(6): 1431-2.

62. Azhar A, Khan WH, Khan PA, Alhosaini K, Owais M, Ahmad A. Mucormycosis and COVID-19 pandemic: Clinical and diagnostic approach. *J Infect Public Health.* 2022; 15 (4): 466-79.

63. Kozel TR, Wickes B. Fungal diagnostics. *Cold Spring Harb Perspect Med.* 2014; 4 (4): a019299.

64. Reed C, Bryant R, Ibrahim AS, Edwards Jr, Filler SG, Goldberg R, et al. Combination polyene-caspofungin treatment of rhino-orbital-cerebral mucormycosis. *Clin Infect Dis.* 2008; 47 (3): 364-71.

65. Candrilli S, Mausekopf J. How much does a hospital day cost. In 11th Annual International Meeting of the International Society for Pharmacoeconomics and Outcomes Research. 2006.

66. Spellberg B, Fu Y, Edwards Jr, Ibrahim AS. Combination therapy with amphotericin B lipid complex and caspofungin acetate of disseminated zygomycosis in diabetic ketoacidotic mice. *Antimicrob. Agents Chemother.* 2005; 49 (2): 830-2.

67. Ibrahim AS, Bowman JC, Avanesian V, Brown K, Spellberg B, Edwards Jr, et al. Caspofungin inhibits *Rhizopus oryzae* 1, 3- β -d-glucan synthase, lowers burden in brain measured by quantitative PCR, and improves survival at a low but not a high dose during murine disseminated zygomycosis. *Antimicrob. Agents Chemother.* 2005; 49 (2): 721-7.

Cite this article:

Saberi-Hasanabadi P, Farmad ME, Ataee R. Mucormycosis: An Emerging Fungal Infection in the COVID-19 Pandemic. *J Med Microbiol Infect Dis*, 2024; 12 (2): 84-99. DOI: 10.61186/JoMMID.12.2.84.