

Exacerbation of Activated Latent Tuberculosis Following COVID-19: A Case Report

Lautika Sonkar^{1*}, Rampal Singh², Jagdamba Sharan³, Deepika Verma⁴

¹Department of Microbiology, Rohilkhand Medical College and Hospital, Bareilly, 243006, Uttar Pradesh, India;

²Department of Anaesthesiology, Rohilkhand Medical College and Hospital, Bareilly, 243006, Uttar Pradesh, India;

³Department of Surgery, Rohilkhand Medical College and Hospital, Bareilly, 243006, Uttar Pradesh, India;

⁴Department of Microbiology, Rohilkhand Medical College and Hospital, Bareilly, 243006, Uttar Pradesh, India.

ARTICLE INFO

Case Report

Keywords: COVID-19, Exacerbation, Latent tuberculosis, Supraclavicular lymphadenopathy

Received: 30 Jul. 2022

Received in revised form: 17 Sep. 2022

Accepted: 22 Oct. 2022

DOI: 10.52547/JoMMID.10.4.204

*Correspondence

Email: lautikasonkar@gmail.com

Tel: +919457222007

Fax:

© The Author(s)



ABSTRACT

While the COVID-19 pandemic affects millions, other infectious diseases might be overlooked. One of these crucial diseases is tuberculosis (TB), a highly infectious bacterial respiratory disease. According to WHO, TB is among the top 10 causes of death globally, with about one-quarter of the world's population infected. COVID-19 has emerged as a potential risk factor for TB in highly prevalent countries because of immunosuppression. This case report highlights a female patient who presented with swelling over the left supraclavicular region, which was very slow in progression. Following COVID-19 infection, a significant increase in swelling within a short time occurred, which was associated with easy fatigability, loss of appetite, generalized weakness, and significant weight loss. Based on investigations, a TB diagnosis was made. Few studies are available regarding the exacerbation of activated latent tuberculosis following COVID-19. Hence, this case report could help in screening and managing such cases.

INTRODUCTION

Tuberculosis (TB) has been a significant public health problem and among the top ten causes of mortality globally, long before COVID-19 became a priority. It has infected one-quarter of the world's population, and over 95% of cases are found in low and middle-income countries [1]. TB occurs as an active and latent infection. In both conditions, the individuals' immunity is suppressed, and COVID-19 is known to readily infect immunocompromised individuals compared to those with a healthy immune system [2]. Several risk factors contribute to tuberculosis reactivation, such as being born in a highly prevalent country, diabetes mellitus, and the use of corticosteroids.

In contrast, in intensive care units, acute kidney injury and hemodialysis for more than one month have been documented in various studies [3]. During the ongoing pandemic, COVID-19 has become a potential risk factor for tuberculosis in highly prevalent countries. This

infection might affect individuals with latent TB and make them prone to the active form of the disease [2], causing a considerable impact on morbidity, mortality, and the economy [4].

TB and COVID-19 affect the lungs and interfere with the host immune system. Besides the reactivation of pulmonary tuberculosis, unusual clinical manifestations like cervical lymphadenopathy happen in the mild form of COVID-19 [5]. Reactivating latent TB after COVID-19, mainly in TB endemic areas, might affect the global health and economic situation and will surely raise the incidence of active TB. Therefore, screening of latent TB in COVID-19 patients with atypical presentation should be considered.

This case report describes the exacerbation of latent TB following COVID-19 infection.

CASE REPORT

A 65-year-old female patient came to Rohilkhand Medical College and Hospital, Bareilly, India,

complaining of swelling over the left supraclavicular region (Fig. 1).

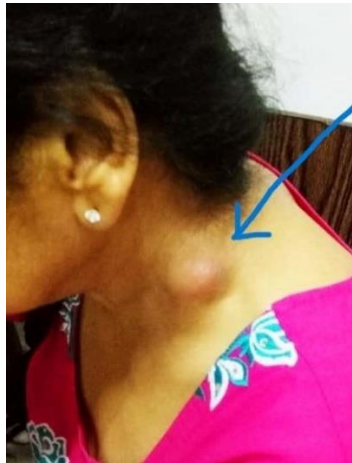

Fig. 1. Supraclavicular swelling on the left side of the base of the neck.

The patient noticed a peanut-size swelling over the left supraclavicular region two years ago, with no effect on the patient's routine activity. It was very slow in progression and ignored by her. The patient had no diabetes or hypertension but had a history of renal tuberculosis 30 years back, for which she had taken complete treatment of antitubercular drugs and was cured completely. In April 2021, the patient developed a low-grade fever, cough, sore throat, and an oxygen saturation above 95%. She was diagnosed with COVID-19 by Real-Time Reverse Transcriptase Polymerase Chain Reaction (RT-PCR) test, for which she consulted a doctor and recovered completely with no complications. Following the

COVID-19 infection, the patient had a significant increase in the size of swelling over 2-3 months. She also complained of generalized weakness, loss of appetite, easy fatigability, low-grade fever, and significant weight loss. Neck examination revealed left supraclavicular swelling measuring ~2×3 cm, non-tender with no visible punctum. The skin over the swelling was shiny and erythematous. She was referred to Microbiology Department for culture and sensitivity test and Ziehl Neelsen (ZN) staining. Fine needle aspiration yielded frank pus. The bacterial culture and sensitivity report of the sample was sterile, but ZN staining revealed red-colored acid-fast bacilli (Fig. 2.).




Fig. 2. Ziehl Neelsen staining showing red-colored rod-shaped acid-fast bacilli.

Also, a sample was sent for the cartridge-based nucleic acid amplification test (CBNAAT), which detected *Mycobacterium tuberculosis* sensitive to rifampicin. The patient was referred to TB and Chest Department for

latent tuberculosis treatment. The patient's chest X-ray was normal, and she was prescribed to start an anti-tubercular five-drug regimen, including isoniazid, rifampicin, pyrazinamide, ethambutol, and levofloxacin

750 mg for two months, followed by isoniazid, rifampicin, ethambutol and levofloxacin 750 mg for next six months.

During the treatment, the swelling gradually shrank (Fig. 3).

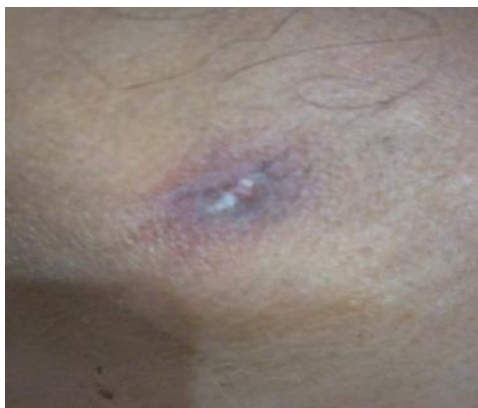

Fig. 3. Healed lesion after antitubercular drug regimen.

The patient was advised for ultrasonography (USG) during the follow-up visit. USG showed multiple enlarged necrotic lymph nodes in the left supraclavicular region, with a few showing conglomerations. By the end of the treatment, lymphadenopathy was resolved, and the patient's weight increased from 54 to 62 kg.

DISCUSSION

Post-COVID-19 infection reactivation of latent tuberculosis is one of the main reasons for active tuberculosis [3]. The mechanism of reactivation of latent tuberculosis is not fully understood. In healthy patients, due to robust immune response, granuloma formation occurs, preventing active tuberculosis development, whereas, in immunocompromised patients, reactivation of tuberculosis occurs [6]. Several risk factors contribute to tuberculosis reactivation, such as human immunodeficiency virus coinfection, organ transplantation, tumor necrosis factor- α blockers, silicosis, close contact exposure, or chronic renal failure requiring dialysis [7].

Our patient did not have any risk factors except COVID-19. SARS-CoV-2 and *M. tuberculosis* involve cell-mediated immunity and trigger high levels of cytokines leading to disease severity [8]. However, the role of COVID-19 in the reactivation of latent tuberculosis remains to be understood. Several studies have reported lymphopenia, depletion of TH4 cells, T-cell exhaustion (defined as progressive loss of effector function due to prolonged antigen stimulation), and cytokine storm, eventually leading to immune dysregulation. In addition, studies have reported the activation of latent tuberculosis in COVID-19 patients treated with tocilizumab [3], which points to the potential role of interleukin-6 in tuberculosis reactivation following COVID-19 infection.

In this case report, we described the exacerbation of activated latent tuberculosis following COVID-19, manifested as supraclavicular lymphadenopathy, an

atypical presentation. Gupta *et al.* (2020) studied 22 COVID-19 patients with active/treated tuberculosis, 13 active TB cases, and nine previously treated TB cases. In active cases, nine had pulmonary, and four had extrapulmonary TB, including cerebral tuberculoma, pleural effusion, cervical lymphadenopathy, and disseminated [9]. Tadolini *et al.* (2020) conducted a large multicentric observational study including COVID-19 patients with pulmonary and extrapulmonary TB. The most common sites for extrapulmonary TB were bone, larynx, central nervous system, lymph nodes, and peritoneal, gastrointestinal, genitourinary, pleural, and spinal tissues [10]. Ala *et al.* (2022) also reported a case of cervical and preauricular lymphadenopathies resulting from local humoral immune response leading to lymph node enlargement due to excessive inflammatory reactions [11]. Several other studies also reported more prevalent cases of pulmonary tuberculosis than extrapulmonary tuberculosis [12, 13, 14].

Since there are few case reports on extrapulmonary tuberculosis, the activation of latent tuberculosis following COVID-19 is yet to be investigated.

This case report highlights the exacerbation of latent tuberculosis following COVID-19 infection, possibly due to immunosuppression. As TB is of high prevalence in India and is stricken severely by the COVID-19 pandemic, screening for latent tuberculosis must be taken into account, especially in high-risk patients like HIV coinfection, organ transplantations, tumor necrosis factor- α blockers, silicosis, close contact exposure, or chronic renal failure requiring dialysis and on COVID-19 treatment.

REFERENCES

1. Friedman A, DeGeorge KC. Reactivation of latent tuberculosis in a COVID-19 patient on corticosteroid treatment. *BMJ Case Rep.* 2022; 15 (5): e247562.

Sonkar et al.

2. Sekaran S, Jagani RP, Waleed MS, Celi CMV, Marzban S. Latent tuberculosis and COVID-19 disease. *Discov Rep.* 2021; 4 (3): e26.
3. Pozdnyakov A, Jin A, Bader M. Reactivation of Pulmonary Tuberculosis in a Patient With COVID-19. *Infect Dis Clin Pract.* 2021; 29 (6): e468–e70.
4. Carlos WG, Dela Cruz CS, Cao B, Pasnick S, Jamil S. Novel Wuhan (2019-nCoV) Coronavirus. *Am J Respir Crit Care Med.* 2020; 201 (4): 7-8.
5. Krajewska J, Krajewski W, Zub K, Zatoński T. COVID-19 in otolaryngologist practice: a review of current knowledge. *Eur Arch Otorhinolaryngol.* 2020; 277 (7): 1885–97.
6. Flynn JL, Chan J. Tuberculosis: latency and reactivation. *Infect Immun.* 2001; 69 (7): 4195-201.
7. Ai JW, Ruan QL, Liu QH, Zhang WH. Updates on the risk factors for latent tuberculosis reactivation and their managements. *Emerg Microbes Infect.* 2016; 5 (2): e10.
8. Sheerin D, Abhimanyu, Wang X, Johnson WE, Coussens A. Systematic evaluation of transcriptomic disease risk and diagnostic biomarker overlap between COVID-19 and tuberculosis: a patient-level meta-analysis. *medRxiv [Preprint].* 2020.
9. Gupta, N, Ish P, Gupta A, Malhotra N, Caminero JA, Singla R, et al. A profile of a retrospective cohort of 22 patients with COVID-19 and active/treated tuberculosis. *Eur Respir J.* 2020; 56 (5): 2003408.
10. Tadolini M, Codecasa LR, García-García J-M, Blanc F-X, Borisov S, Alffenaar J-W, et al. Active tuberculosis, sequelae and COVID-19 co-infection: first cohort of 49 cases. *Eur Respir J.* 2020; 56 (1): 2001398.
11. Ala A, Habtemariam S, Vahdati SS, Rezaabakhsh A. Cervical and preauricular lymphadenopathies as atypical manifestations in the setting of COVID-19: a case report. *Future Virol.* 2022; 17 (4): 215–9.
12. AlKhateeb MH, Aziz A, Eltahir M, Elzouki A. Bilateral foot-drop secondary to axonal neuropathy in a tuberculosis patient with co-infection of COVID-19: A case report. *Cureus.* 2020; 12 (11): e11734.
13. Liu C, Yu Y, Fleming J, Wang T, Shen S, Wang Y, et al. Severe COVID-19 cases with a history of active or latent tuberculosis. *Int J Tuberc Lung Dis.* 2020; 24 (7): 747–9.
14. Sarma U, Mishra V, Goel J, Yadav S, Sharma S, Sherawat RK. COVID-19 pneumonia with Delayed Viral Clearance in a patient with Active Drug-resistant Pulmonary Tuberculosis. *Indian J Crit Care Med.* 2020; 24 (11): 1132–4.

Cite this article:

Sonkar L, Singh R, Sharan J, Verma D. Exacerbation of Activated Latent Tuberculosis Following COVID-19: A Case Report. *J Med Microbiol Infect Dis*, 2022; 10 (4): 204-207. DOI: 10.52547/JoMMID.10.4.204