

Tocilizumab in Post Hematopoietic Stem Cell Transplant COVID-19: A Pediatric Case Report

Tahereh Rostami¹ , Neda Alijani² , Azadeh Kiumarsi^{1*} , Soroush Rad³ , Seied Amirhosein Mirhoseini³ ,
Mohammadreza Rostami³ , Amir Hesabi¹ , Seyed Ali Mousavi³ , Seied Asadollah Mousavi³ 

¹Department of Pediatric Cell Therapy, Research Institute for Oncology, Hematology and Cell Therapy, Tehran University of Medical Sciences, Tehran, Iran; ²Department of Infectious Diseases, Research Institute for Oncology, Hematology and Cell Therapy, Tehran University of Medical Sciences, Tehran, Iran; ³Research Institute for Oncology, Hematology and Cell Therapy, Tehran University of Medical Sciences, Tehran, Iran

ARTICLE INFO

Case Report

Keywords: Post Hematopoietic Stem Cell Transplantation, COVID-19, Mucopolysaccharidosis

Received: 18 Sep. 2021

Received in revised form: 19 Oct. 2021

Accepted: 27 Oct. 2021

DOI: 10.52547/JoMMID.9.4.225

*Correspondence

Email: akiumarsi@sina.tums.ac.ir

Tel: +989121037104

Fax: +98218802 9397

© The Author(s)



ABSTRACT

Hematopoietic stem cell transplantation (HSCT) severely undermines the recipients' immune status and makes them prone to complications following viral infection. Here, we report a 3-year-old boy with mucopolysaccharidosis type VI who acquired SARS-CoV-2 infection after HSCT. The boy was diagnosed with SARS-CoV-2 during the post-transplant period (19 days after HSCT) when dealing with acute graft versus host disease (GVHD). He was successfully treated with remdesivir and tocilizumab and recovered. Well-timed treatment with tocilizumab might reduce the risk of invasive mechanical ventilation and death in patients with severe COVID-19 pneumonia in the early post HSCT period.

INTRODUCTION

SARS-CoV-2 has recently infected a significant number of people worldwide. Even though severe coronavirus disease 2019 (COVID-19) symptoms develop in a minority of patients, the associated complications occur more often in immunocompromised individuals like hematopoietic stem cell transplantation (HSCT) recipients.

COVID-19 is a confusing and divergent disease, and unfortunately, there is no standard treatment available. Thus, HSCT clinicians are re-organizing their medical care to alleviate complications without giving up patients' inquiries. Consequently, decisions about the treatment for COVID-19 in these patients are made based on expert opinions.

Our pediatric HSCT ward, affiliated with the Tehran University of medical sciences (TUMS), is the first and the most referred national center for pediatric HSCT. On

Feb. 2020, the first COVID-19 case was officially announced in Iran [1]. Since then, we have obeyed the modified rules and regulations to reduce the risk of SARS-CoV-2 infection in our patients and our staff [2]. Nevertheless, in Sep. 2020, we encountered the first case of SARS-CoV-2 infection in our pediatric HSCT ward. Here, we report a unique case of a child with viral pneumonia caused by new SARS-CoV-2 diagnosed after HSCT that recovered by well-timed treatment.

CASE REPORT

A three-year-old boy was admitted to our pediatric HSCT ward in Shariati Hospital, Tehran, Iran, on August 14, 2020. He was a second-born child of consanguineous parents. The clinical examination revealed coarse facies, a short neck, short hands with stubby digits, corneal clouding, and no organomegaly. He weighed 14 kg (75th centile), and his standing height was 90 cm (25th centile).

Motor milestones, muscle tone, and joint range of motion were normal for the age. He had an acceptable speech development. His auditory brainstem response (ABR) test was compatible with mild hearing loss in both ears. Foramen magnum stenosis was reported in brain CT scan as well as hypoplasia of T12 vertebral body with central beaking in thoracic CT scan. An echocardiogram demonstrated PFO, mild LVH and LVE, thickened MV with MVP and severe MR, no MS, thickened AO with AVP, mild TR, and PI, good LVEF (70%). He had a normal elder brother, aged 13 years, who was not HLA matched with him. His family history was also found to be negative for MPS. All routine hematological and biochemical tests were performed at the time of admission, all within normal limits. At the time of admission, the specific real-time PCR for identifying SARS-CoV-2, using nasopharyngeal swabs, was negative in the patient and her mother, who was entering the ward as his caregiver.

The myeloablative conditioning regimen comprised cyclophosphamide 200 mg/kg, busulphan 17.6 mg/kg, and thymoglobulin 10 mg/kg. HSCT with peripheral blood-derived stem cells (5.5×10^6 /kg CD34 positive cells) from an HLA-matched unrelated donor (match 10/10) was performed on August 25, 2020. He received graft-versus-host disease prophylaxis consisting of cyclosporine (since pretransplant day -2) and MTX (on post-transplant days +1, +3, +6, +11). On the fifth day after HSCT, the patient developed a 38.5°C fever. Empiric antibiotic therapy with meropenem and vancomycin was initiated, and the fever diminished. However, on post-transplant days +11, liposomal amphotericin was also empirically initiated due to fever and neutropenia. He developed stage 3 skin GVHD on day +14 post-HSCT, and 1mg/kg methylprednisolone was initiated for him and continued until day +40 post-HSCT when it was doubled due to the occurrence of gastrointestinal stage 4 GVHD. Myeloid and platelet engraftment occurred on +12 day and +20 day post-HSCT, respectively. Chimerism by STR revealed 100% donor cells 15 days after transplant.

On the +15 day post-transplant day, he presented with fever and tachypnea. PCR test for SARS-CoV-2 using a nasopharyngeal swab became positive the next day. The chest CT scan revealed patchy ground-glass opacities in both lungs (Fig. 1A.). After COVID-19 confirmation, considering the blood oxygen saturation of <95% on room air, atazanavir/ritonavir was started for him. However, due to the large size of the pills, he could not swallow them. We kept the patient in our pediatric HSCT ward, but we boosted our protective measures specifically for this patient, including the use of class N95/FFP3 personal protective equipment, specifying a nurse each shift to enter his room without permitting her to enter other patients' rooms.

On day +18 post-HSCT, remdesivir was initiated at a 5 mg/kg/day dose and continued for 10 days. The

respiratory symptoms and fever improved gradually, and the blood oxygen saturation raised to 95% on room air. However, on +24 days post-HSCT, he developed fever, respiratory distress, and hypoxia again. The chest CT scan revealed bilateral multifocal dominantly patchy ground-glass opacities and consolidations suggestive of COVID-19 pneumonia (Fig. 1B). We decided to administer tocilizumab (two doses, at 8 mg/kg intravenously, every 12 h) as the interleukin-6 level increased to 88.5 pg/ml. Figure 2 exhibits the continuous monitoring of the patient's laboratory indices, and figure 3 demonstrates the timings of medications administration. The patient's condition improved significantly within two days; he became afebrile, and his tachypnea diminished. The interleukin-6 level decreased to 24 pg/ml, and the patient gradually reached normal blood oxygen levels on room air. The chest CT scan on day +40 post-HSCT showed reduced parenchymal opacities than the previous scan (Fig. 1C.).

The patient developed stage 4 of gastrointestinal GVHD on day +40 post-HSCT, and we increased the methylprednisolone dose to 2mg/kg/day. However, not responding to the first line of acute GVHD treatment, mycophenolate mofetil was added on day +47 post-HSCT. Finally, the patient was discharged with a good condition on day +67 post-HSCT.

DISCUSSION

Infection with SARS-CoV-2 is spreading rapidly worldwide, and our knowledge of the clinic and epidemiological features of COVID-19 is changing. Adults are the main focus in most studies; however, identifying the clinicopathologic features in pediatric patients is crucial to foresee the severity of the disease and adopt proper treatment [3]. Milder symptoms are more common in children than in adult patients, and in the youngest age group, the death rate is exceptionally lower, though data concerning the outcomes of COVID-19 in immunocompromised pediatric patients and HSCT recipients are scarce [4-7].

The pathogenesis of COVID-19 remains unclear; however, high serum levels of pro-inflammatory cytokines, including interleukins 6, 1, and 12, together with tumor necrosis factor, leading to a cytokine storm, is reported in COVID-19 patients admitted in intensive care units (ICU), and the occurrence of cytokine storm syndrome proportionally correlates with disease severity [8-12]. Interleukins 6 (IL-6) appears to be involved in the inflammatory storm leading to alveolar-capillary blood-gas exchange dysfunction. This finding suggests that IL-6 may be a potential target in treating COVID-19, and tocilizumab, an IL-6 receptor antagonist, might decrease the risk of acute respiratory distress syndrome (ARDS) by alleviating the cytokine storm in the lungs [13]. Fu *et al.* (2020) recognized that T cells and monocytes provoke an inflammatory storm with a high level of IL-6. Hence, monoclonal antibodies as tocilizumab, targeting the IL-6 pathways, could restrict the potential inflammatory storm [14].

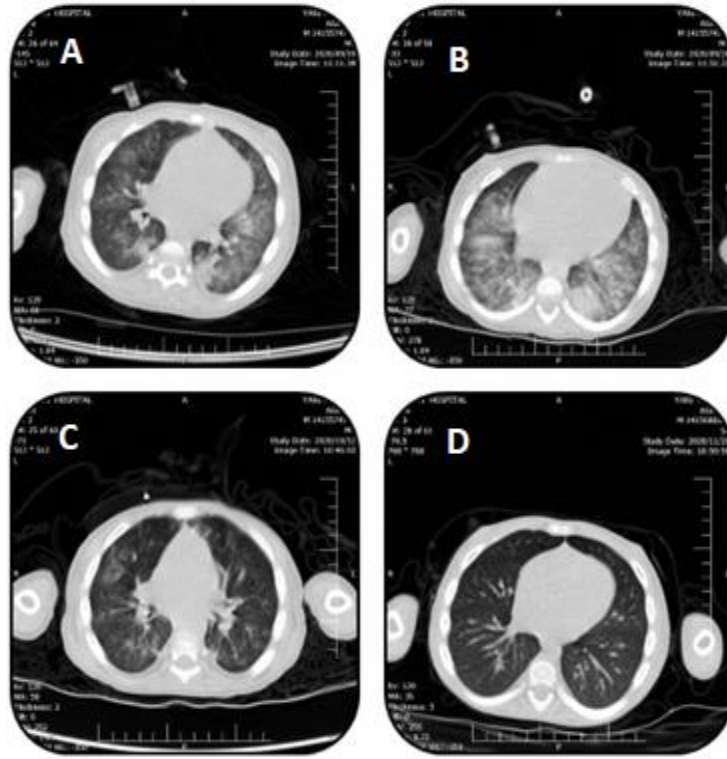


Fig. 1. Chest CT from the HSCT patient at different intervals. **A)** Patchy ground-glass opacities in both lungs on day +16 post-HSCT; **B)** bilateral multifocal dominantly patchy ground-glass opacities and consolidations on day +24 post-HSCT; **C)** reduced parenchymal opacities compared to the previous CT on day +40 post-HSCT; **D)** complete resolution of opacities on day +90 post-HSCT.

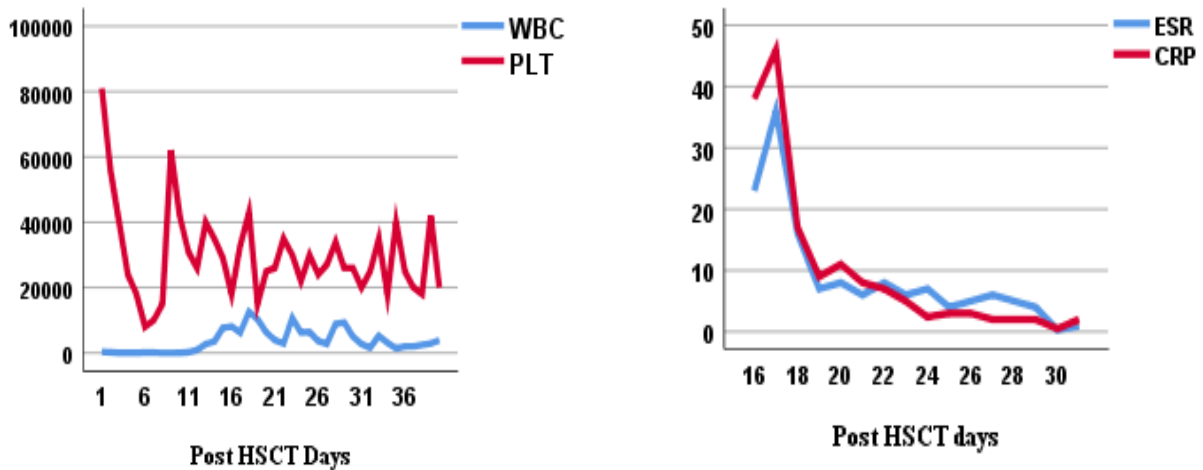


Fig. 2. Laboratory indices of HSCT patient at days post HSC.

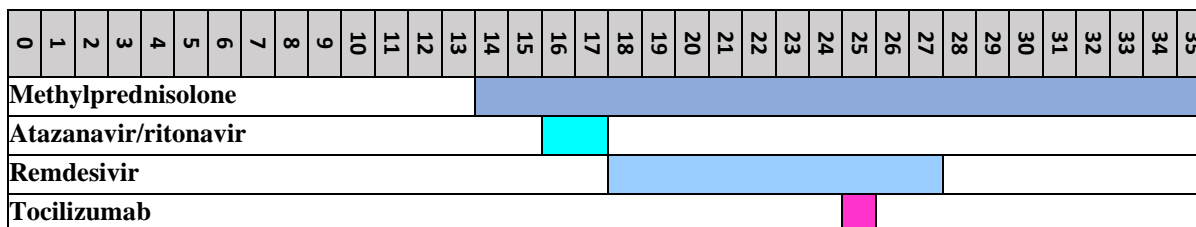


Fig. 3. Timing of drug administration for the HSCT patient.

Our patient's high plasma IL-6 level and the reinitiation of dyspnea and saturation drop prompted us to administer tocilizumab, which successfully led to rapid clinical improvement. Also, IL-6 level, C-reactive protein (CRP), and erythrocyte sedimentation rate (ESR) decreased significantly after the tocilizumab administration. Our patient encountered no significant alteration in hematologic parameters and no drug-induced adverse effects after tocilizumab administration.

Michot *et al.* (2020) described efficacious administration of tocilizumab to a patient with clear cell renal cell carcinoma diagnosed with COVID-19 [15]. In addition to the standard of care in Italy, tocilizumab administration to 179 severe COVID-19 patients resulted in a lower death rate or ICU admissions [16]. In another randomized clinical trial, compared with the standard of care, an advantageous effect of tocilizumab was anticipated [17]. On the same road, Kewan *et al.* (2020) interpreted that tocilizumab administration led to a significantly shorter duration of invasive ventilation and vasopressor support requirement and shorter median time of clinical improvement in patients with severe COVID-19 [18]. A multicenter study showed a reduced mortality rate in 210 ICU admitted COVID-19 patients who received tocilizumab [19].

However, in a randomized, double-blind, placebo-controlled trial, tocilizumab was ineffective in intubation or death prevention of moderately-ill COVID-19 patients [20]. In China, 12 COVID-19 patients with raised IL-6 who had received tocilizumab showed clinical improvement; however, two patients died due to a persistent drop in lymphocyte counts, and one patient's condition was exacerbated after the tocilizumab administration [21]. In another report from Wuhan, three out of seven critically ill patients who received only a single dose of tocilizumab died, and one patient was clinically aggravated [22]. Finally, in a systematic review, Cortegiani *et al.* (2020) concluded that evidence on the clinical efficacy and safety of tocilizumab in COVID-19 patients is still insufficient, and ethically, it could be only used in approved clinical trials [23].

In brief, COVID-19 might lead to a cytokine storm phase in post-HSCT patients, and treatment with anti-IL-6 receptor seems to be a promising therapy. It is vital for health care providers to be aware of COVID-19 in the HSCT settings and consider different treatment options in these patients.

ACKNOWLEDGMENT

The authors acknowledge the pediatric infectious disease specialist, Dr. Shahnaz Armin, for her invaluable input and perspective on the management of this patient. Our gratitude goes to our pediatric nurses, especially Ashrafsadat Hoseini and Mona Pourabbas.

CONFLICT OF INTEREST

The authors declare that there are no conflicts of interest associated with this manuscript.

REFERENCES

1. Takian A, Raoofi A, Kazempour-Ardebili S. COVID-19 battle during the toughest sanctions against Iran. *Lancet*. 2020; 395 (10229): 1035.
2. Rostami T, Mousavi SA, Rad S, Kiumarsi A, Hesabi A, Rostami M, et al. Pediatric Hematopoietic Stem Cell Transplant in the COVID-19 Pandemic: The Problems We Faced and The Strategies We Adopted. *Arch Pediatr Infect Dis*. 2020; 31;8 (4): e104228.
3. Hoang A, Chorath K, Moreira A, Evans M, Burmeister-Morton F, Burmeister F, et al. COVID-19 in 7780 pediatric patients: a systematic review. *EClinicalMedicine*. 2020; 24: 100433.
4. Morand A, Fabre A, Minodier P, Boutin A, Vanel N, Bosdure E, et al. COVID-19 virus and children: What do we know? *Arch Pediatr*. 2020; 27 (3): 117-8.
5. Wu Z, McGoogan JM. Characteristics of and important lessons from the coronavirus disease 2019 (COVID-19) outbreak in China: summary of a report of 72 314 cases from the Chinese Center for Disease Control and Prevention. *Jama*. 2020; 323 (13): 1239-42.
6. Guillen E, Pineiro GJ, Revuelta I, Rodriguez D, Bodro M, Moreno A, et al. Case report of COVID-19 in a kidney transplant recipient: does immunosuppression alter the clinical presentation? *Am J Transplant*. 2020; 20 (7):1875-8.
7. Vickers NJ. Animal communication: when i'm calling you, will you answer too? *Curr Biol*. 2017; 27 (14): R713-5.
8. Huang C, Wang Y, Li X, Ren L, Zhao J, Hu Y, et al. Clinical features of patients infected with 2019 novel coronavirus in Wuhan, China. *Lancet*. 2020; 395 (10223): 497-506.
9. Channappanavar R, Perlman S. Pathogenic human coronavirus infections: causes and consequences of cytokine storm and immunopathology. *Semin Immunopathol*. 2017; 39 (5): 529-539.

Rostami et al.

10. Wong CK, Lam CW, Wu AK, Ip WK, Lee NL, Chan IH, et al. Plasma inflammatory cytokines and chemokines in severe acute respiratory syndrome. *Clin Exp Immunol.* 2004; 136 (1): 95-103.
11. Conti P, Ronconi G, Caraffa AL, Gallenga CE, Ross R, Frydas I, et al. Induction of pro-inflammatory cytokines (IL-1 and IL-6) and lung inflammation by Coronavirus-19 (COVI-19 or SARS-CoV-2): anti-inflammatory strategies. *J Biol Regul Homeost Agents.* 2020; 14; 34 (2): 327-31.
12. Chen N, Zhou M, Dong X, Qu J, Gong F, Han Y, et al. Epidemiological and clinical characteristics of 99 cases of 2019 novel coronavirus pneumonia in Wuhan, China: a descriptive study. *Lancet.* 2020; 395 (10223): 507-13.
13. Xu Z, Shi L, Wang Y, Zhang J, Huang L, Zhang C, et al. Pathological findings of COVID-19 associated with acute respiratory distress syndrome. *Lancet Respir Med.* 2020; 8 (4): 420-2.
14. Fu B, Xu X, Wei H. Why tocilizumab could be an effective treatment for severe COVID-19? *J Transl Med.* 2020; 18 (1): 164.
15. Michot JM, Albiges L, Chaput N, Saada V, Pommeret F, Griscelli F, et al. Tocilizumab, an anti-IL-6 receptor antibody, to treat COVID-19-related respiratory failure: a case report. *Ann Oncol.* 2020; 31 (7): 961-4.
16. Guaraldi G, Meschiari M, Cozzi-Lepri A, Milic J, Tonelli R, Menozzi M, et al. Tocilizumab in patients with severe COVID-19: a retrospective cohort study. *The Lancet Rheumatology.* 2020; 2 (8): e474-84.
17. Veiga VC, Prats JA, Farias DL, Rosa RG, Dourado LK, Zampieri FG, et al. Effect of tocilizumab on clinical outcomes at 15 days in patients with severe or critical coronavirus disease 2019: randomised controlled trial. *Bmj.* 2021; 372 (84).
18. Kewan T, Covut F, Al-Jaghbeer MJ, Rose L, Gopalakrishna KV, Akbik B. Tocilizumab for treatment of patients with severe COVID-19: A retrospective cohort study. *EClinicalMedicine.* 2020; 24: 100418.
19. Biran N, Ip A, Ahn J, Go RC, Wang S, Mathura S, et al. Tocilizumab among patients with COVID-19 in the intensive care unit: a multicentre observational study. *The Lancet Rheumatology.* 2020; 2 (10): e603-12.
20. Stone JH, Frigault MJ, Serling-Boyd NJ, Fernandes AD, Harvey L, Foulkes AS, et al. Efficacy of tocilizumab in patients hospitalized with COVID-19. *N Engl J Med.* 2020; 383 (24): 2333-44.
21. Wang Y, Mao Q, Zhou X. Does tocilizumab have a magical therapeutic effect on COVID-19 patients without obvious adverse reactions? *Proc Natl Acad Sci U S A.* 2020. 117 (49): 30896-7.
22. Luo P, Liu Y, Qiu L, Liu X, Liu D, Li J. Tocilizumab treatment in COVID-19: A single center experience. *J Med Virol.* 2020; 92 (7): 814-8.
23. Cortegiani A, Ippolito M, Greco M, Granone V, Protti A, Gregoretti C, et al. Rationale and evidence on the use of tocilizumab in COVID-19: a systematic review. *Pulmonology.* 2021; 27 (1): 52-66.

Cite this article:

Rostami T, Alijani N, Kiumarsi A, Rad S, Mirhoseini SA, Rostami M, Hesabi A, Mousavi SA, Mousavi SA. Tocilizumab in Post Hematopoietic Stem Cell Transplant COVID-19: A Pediatric Case Report. *J Med Microbiol Infect Dis*, 2021; 9 (4): 225-229. DOI: 10.52547/JoMMID.9.4.225.