

## *Trichosomoides crassicauda* Infection in Laboratory Rats with Histopathological Description in the Bladder Tissue

Faezeh Najafi<sup>1</sup>, Maede Taghavi Ghadikolai<sup>2</sup>, Saied Reza Naddaf<sup>3</sup>, Hamid Hasanpour<sup>1</sup>, Iraj Mobedi<sup>1</sup>, Gholamreza Mowlavi<sup>1,4\*</sup>

<sup>1</sup>Department of Parasitology and Mycology, School of Public Health, Tehran University of Medical Sciences, Tehran, Iran; <sup>2</sup>Department of Biology, Faculty of Sciences, University of Mohaghegh Ardabili, Ardabil, Iran; <sup>3</sup>Department of Parasitology, Research Center for Emerging and Reemerging Diseases Pasteur Institute of Iran, Tehran, Iran; <sup>4</sup>Center for Research of Endemic Parasites of Iran (CREPI), Tehran University of Medical Sciences, Tehran, Iran

Received Oct 09, 2017; Accepted Dec 09, 2017

**Introduction:** Some postgraduate students reported the presence of a nematode infection, presumably, *Trichosomoides crassicauda* in the urinary bladder of rats (*Rattus norvegicus*) from the animal house of Tehran University of Medical Sciences (TUMS). We prompted to explore the prevalence of this infection among the rats of animal houses belonging to medical and veterinary research centers in Tehran. We also described the histopathological changes in the bladder tissue of the infected rats. **Methods:** We collected 214 adult rats (*R. norvegicus*) from four animal houses including TUMS in Tehran. The urine of 112 animals was collected during 24 h and inspected microscopically for helminths eggs. Then, the rats were euthanized, sacrificed and dissected; their bladders were removed and examined under a stereomicroscope for the presence of worms and histopathological changes. **Results:** Out of 112 urine samples checked, 16 contained *T. crassicauda* eggs. Out of 214 rats, 114 showed infection urinary bladder with the nematode *T. crassicauda*. The histopathological changes in the urinary bladder included hyperemia, edema, hyperplasia, and metaplasia. In the transitional epithelium, the features of gravid female nematodes, with an egg-filled uterus were visible. **Conclusion:** *Trichosomoides crassicauda* is a prevalent infection in laboratory rats of research centers in Tehran and its identification cannot be made merely based on urine examination of the rats. *J Med Microbiol Infect Dis*, 2017, 5 (1-2): 31-34.

**Keywords:** *Trichosomoides crassicauda*, Laboratory Rats, Histopathological Changes.

### INTRODUCTION

Experiments in different fields of biology and medical sciences depend on various laboratory animals. Rats are the second most utilized experimental animals in research studies worldwide, after laboratory mice [1]. Different lines of biomedical science such as organ transplantation, immunology, genetics, cancer research, pharmacology, physiology and neuroscience use rats as animal models [2]. Most of the experiments might be affected by the interaction between the animals and the pathogens including the parasites that commonly exist with no obvious clinical manifestations, rendering the obtained results unreliable [1, 3]. The nematode *Trichosomoides crassicauda* was firstly described by Bellingham in 1840 in the urinary bladder of rat [4]. It is known as a non-pathogenic nematode living in the urinary bladder of wild and laboratory rats [5]. In a survey to determine the endoparasite of *Rattus norvegicus*, *T. crassicauda* was the most prevalent helminth parasites among the collected rodents [6]. The male worm of this nematode resides in the uterus or vagina of the adult female [7], demonstrating a unique biological behavior among parasitic helminths. This nematode has a direct life cycle, and infection occurs through the ingestion of contaminated foods and water containing embryonated eggs expelled in the urine [7]. On ingestion, the larvae hatch in the stomach and migrate to the lungs through body cavities or the bloodstream. The larvae

reach the kidneys via the bloodstream and reach the bladder by passing the ureters [7]. The nematodes may be found free in the lumen or in the mucosal tissue of the bladder, causing severe catarrhal cystitis in massive infections [8]. Urinary calculi and bladder tumors may be associated with *T. crassicauda* infection. The larvae cause eosinophilic granulomas [9] and the infections in the bladder may lead to the granulomatous lesion [10]. Some postgraduate students reported the presence of a nematode infection, presumably, *T. crassicauda* in the urinary bladder of the rats from the animal house of Tehran University of Medical Sciences (TUMS). Regarding the potential adverse effect of this infection on the results of research studies, we prompted to explore the prevalence of infection among the rats from the animal houses of four research centers in

**\*Correspondence:** Gholamreza Mowlavi

Department of Medical Parasitology and Mycology, School of Public Health, Tehran University of Medical Science, PurSina St., Keshavarz Blvd., Tehran, Iran, 141556446.

**Email:** molavig@yahoo.com

**Tel:** +98 (21) 88941400 **Fax:** +98 (21) 66462267

Tehran including TUMS. We also described the histopathological changes in the bladder tissue of the infected rats.

## MATERIAL AND METHODS

**Animals.** We collected 214 rats (152 male and 62 female) from four animal houses affiliated with medical and veterinary research center in Tehran, Iran during 2011-2012. The genus and weight of the rats were recorded and kept individually in bird cages.

**Collection of urine samples from rats.** The urine of 112 rats was collected for 24 h in a disposable container installed under the cage. The urines were recovered with a syringe, transported to the laboratory, poured into a plate and after addition of 10% formalin, were examined microscopically with a magnification of 10X for helminth egg.

**Identification of the worm.** The rats were sacrificed by chloroform, dissected and their bladders were examined for helminths under a stereomicroscope with a magnification of 40X. The adult worms were identified based on morphological and morphometric characters described by others [11].

**Histopathology.** The infected tissues were collected and fixed overnight in 10% neutral buffered formalin and dehydrated in an increasing degree of alcohol, *i.e.*, 70%, 85%, 96%, and 100% followed by xylene for 1 h in each step. The tissues were impregnated in molten paraffin for 2 h, and the blocked tissues were sectioned at 4-5  $\mu$ m. The tissue sections were mounted on microscope slides, stained with hematoxylin and eosin and examined under a light microscope with a magnification of 40X [9].

**Statistical analysis.** The data were analyzed with Chi-square test at the 5% levels of significance.

## RESULTS

**Urine examination.** Out of 112 urine samples examined, 16 contained *T. crassicauda* eggs. The eggs were oval, brown, embryonated, and thick-shelled with an operculum at each end.

**The Bladder infection with *T. crassicauda*.** Out of 214 rats examined, 114 (53%) showed infection with *T. crassicauda* in the urinary bladder. Out of the 152 and 62 urinary bladders from male and female rats, 88 (57%) and 26 (41%) were infected with the nematode (Table 1). The infection rate was significantly higher in males than females ( $P<0.05$ ) and was positively associated with the animals' body weight ( $P<0.05$ ) which could be considered as an index of age.

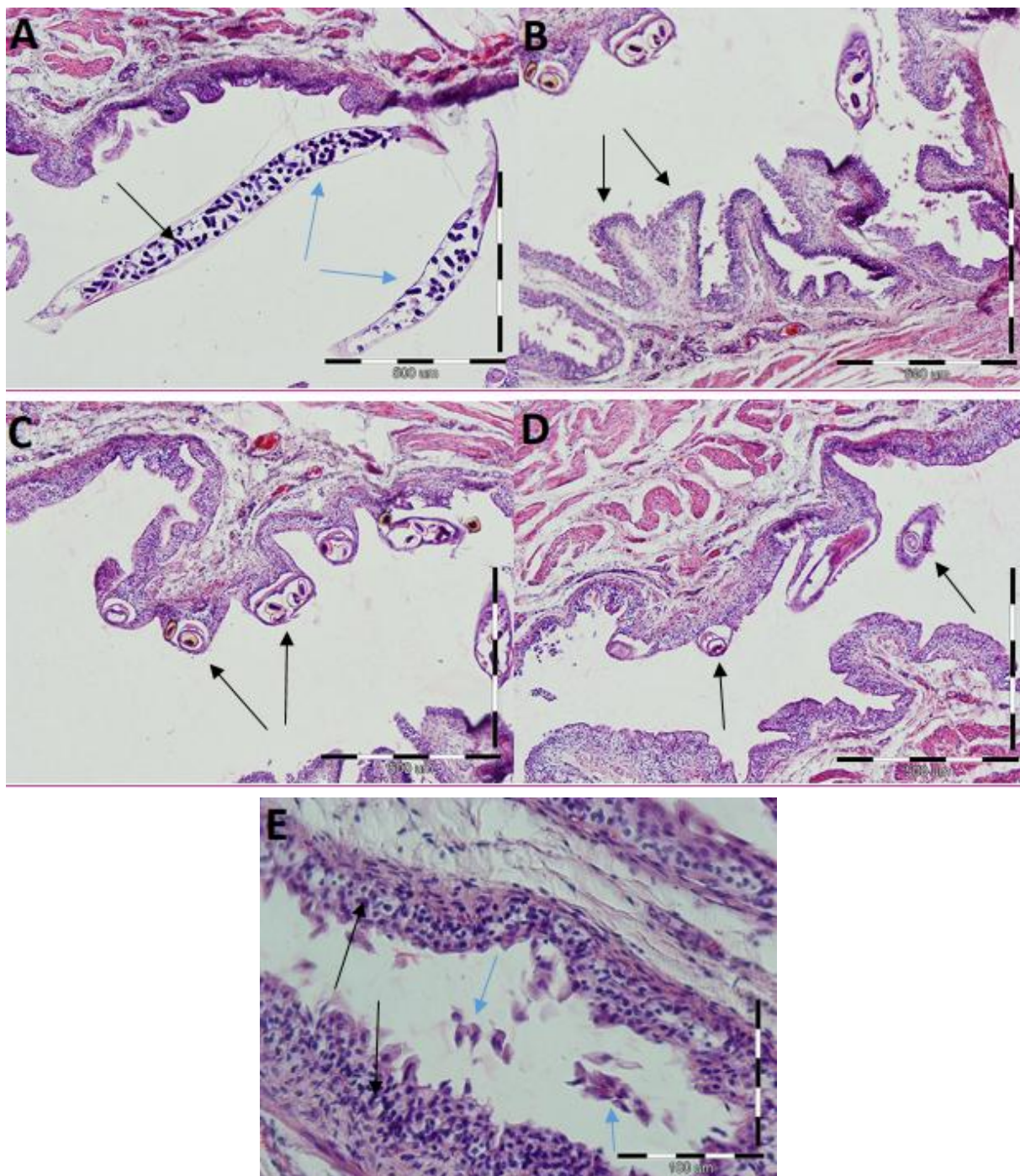
**Histopathological changes of the bladder tissue.** The presence of developing nematodes within the transitional epithelium of urinary bladder had resulted in some pathological changes. Minute well-developed eggs and free mature female *T. crassicauda* with developing eggs were seen in the urinary bladder (Fig. 1A). In infected tissues hyperemia, edema, and hyperplasia of transitional epithelium with a few scattered eosinophils in the submucosa were observed (Fig. 1B). The sections of gravid female nematodes, frequently with an egg-filled uterus were evident in the transitional epithelium (Fig. 1C, and D). Squamous metaplasia of urinary bladder epithelium with a demonstration of desquamation of the epithelial cells and local attenuation of mucosa were other tissue changes in the infected urinary bladders (Fig. 1E).

## DISCUSSION

In this study, we described *T. crassicauda* infection in the laboratory rats from four animal houses in Tehran and demonstrated the histopathological changes of the bladder tissue. The gender of the rats had a significant effect on the rate of infection and the males were found more infected. This could be due to steroid hormones of male rats such as testosterone, which suppress the immune system making the males more vulnerable to the infection than females [12]. Rats, with higher weight, which could be considered as a index of age, were more infected. Moreover, out of the 112 urine samples examined, only 16 had eggs of *T. crassicauda*, which shows the infection cannot be reliably diagnosed merely by urine examination as the eggs are not regularly expelled by the mature worms [13]. Also, the absence of egg in urine may be associated with age of rats as eggs are not usually present in the urine of rats until they are 8-12 weeks old [14]. Previously, in diabetic rats, *T. crassicauda* showed to induce hyperplastic response, inflammation, and papilloma in the bladder epithelium [5]. Also, in the bladder epithelium of infected rats the sections of female worms with embryonated eggs embedded in the epithelium were seen [15]. Death of young rats due to the migration of the larvae to the lungs, pulmonary congestion, and hemorrhage was reported [7, 16]. In this study, the worms and the embryonated eggs in the transitional epithelium of bladder were observed. Histopathology of bladder demonstrated a hyperemic and edematous appearance of the bladder and the presence of eosinophils in submucosa that could be due to inflammatory responses to the worm. Also, proliferations including hyperplasia and squamous metaplasia were seen in the bladder epithelium of infected rats, which are in agreement with previous studies [15, 17].

**Table 1.** The rate of infection in laboratory rats according to the gender

Variable		Infected	Non-infected	Total	Infection rate (%)
Gender	Male	88	64	152	57.89
	Female	26	36	62	41.93
Total		114	100	214	53.27



**Fig. 1.** Histopathological changes in the urinary bladder of *T. crassicauda*-infected rats. (A) embryonated eggs (black arrow) in female worms (blue arrows) in the epithelium; (B) hyperplasia of the transitional epithelium tissue (black arrows); (C, D) the cross sections of gravid female nematodes (black arrows) in the transitional epithelium; (E) squamous metaplasia (black arrows) and desquamation of epithelial cells of the urinary bladder (blue arrows)

Similar studies have shown papilloma, squamous metaplasia, epithelial hyperplasia, tumors and inflammation with or without uroliths in the urinary bladder [17, 18], and accumulation of eosinophils in the lamina propria [15]. No tumor, uroliths or papilloma were observed in the rats examined in this study. The development of uroliths and papilloma may be related to the duration of the epithelium irritation by the parasite [17]. In some studies, examination

of the mucosal surface of bladder did not reveal the worms, which could be due to the transparency of the worms making them undetectable in tissue sections [13]. Also, even in heavy infections, the worms may not be observed in sections as they might be lost during the histotechnique procedures [19]. These findings are in contrast with the result of the present study in which sections of mature worms were clearly observed. Histopathological changes in

rat bladder may happen during the larvae migration within the tissue which interfere with histopathological and hematological experiments [9]. *Trichosomoides crassicauda* disrupts epithelial integrity and damages the permeability barrier of the urothelium [7]. Furthermore, the cell's nucleus of the basal layer of the bladder epithelium multiplies, and an increase in cell size occurs [20]. During maturation of the worms, the urinary bladder is irritated, and the transitional epithelium degenerates [5]. In addition, the epithelium is stratified, and hyperplasia can appear [5]. The hyperplastic epithelium may be a protective site for the adult worms of *T. crassicauda*. Thus no protective immunity may be stimulated in the rats in response to this stage of the infection [7]. The proliferation caused by *T. crassicauda* makes animals harboring this parasite unsuitable for many experiments where bladder histology is examined [10]. The results of the current study indicate that *T. crassicauda* is a prevalent infection among laboratory rats of research centers in Tehran and histopathology revealed as a more reliable approach than urine examination for identifying the infection of laboratory rats with this nematode.

Implementing quarantine programs and appropriate sanitation barriers in animal houses is essential to reduce the infection rate among laboratory rats in biomedical research centers.

## ACKNOWLEDGEMENT

This study was supported financially by Tehran University of Medical Sciences, Tehran, Iran.

## CONFLICT OF INTEREST

The authors declare that there are no conflicts of interest associated with this manuscript.

## REFERENCES

1. Perec-Matysiak A, Okulewicz A, Hildebrand J, Zaleśny G. Helminth parasites of laboratory mice and rats. *Wiad Parazytol.* 2005; 52 (2): 99-102.
2. Gill TJ, Smith GJ, Wissler RW, Kunz HW. The rat as an experimental animal. *Science.* 1989; 245 (4915): 269-76.
3. Najafi F, Rezaie S, Kia E, Mobedi I, Mahmodi M, Salimi M, Hasanpour H, Makki M, Mowlavi G. Intestinal helminths in laboratory mice and rats in four research centers, Tehran, Iran. *J Med Microbiol Infec Dis.* 2014; 2 (4): 130-2.
4. Bellingham O. Catalogue of entozoa indigenous to Ireland, with observations. *Annals of the Magazine of Natural History.* 1840; 4: 343-51.
5. Ozkorkmaz EG. Microscopic investigations in a diabetic rat urinary bladder infected with *Trichosomoides crassicauda*. *J Electron Microsc* (Tokyo). 2011; 60 (4): 261-5.

6. Kia E, Homayouni M, Farahnak A, Mohebbali M, Shojai S. Study of endoparasites of rodents and their zoonotic importance in Ahvaz, south west Iran. *Iranian J Publ Health.* 2001; 30 (1-2): 49-52.
7. Antonakopoulos G, Turton J, Whitfield P, Newman J. Host-parasite interface of the urinary bladder-inhabiting nematode *Trichosomoides crassicauda*: changes induced in the urothelium of infected rats. *Int J Parasitol.* 1991; 21 (2): 187-93.
8. Yokogawa S. On the migratory course of *Trichosomoides crassicauda* (Bellingham) in the body of the final host. *J Parasitol.* 1920; 7 (2): 80-4.
9. Zubaidy AJ, Majeed SK. Pathology of the nematode *Trichosomoides crassicauda* in the urinary bladder of laboratory rats. *Lab Anim.* 1981; 15 (4): 381-4.
10. Chapman W. Infection with *Trichosomoides crassicauda* as a factor in the induction of bladder tumors in rats fed 2-acetylaminofluorene. *Invest Urol.* 1969; 7 (2): 154-9.
11. Flynn RJ. Parasites of laboratory animals. 1st ed. Iowa state University Press: Ames; 1973; 345-6.
12. Hernández-Bello R, Ramirez-Nieto R, Muñoz-Hernández S, Nava-Castro K, Pavón L, Sánchez-Acosta AG, Morales-Montor J. Sex steroids effects on the molting process of the helminth human parasite *Trichinella spiralis*. *J Biomed Biotechnol.* 2011; 1-10.
13. Cornish J, Vanderwee M, Findon G, Miller T. Reliable diagnosis of *Trichosomoides crassicauda* in the urinary bladder of the rat. *Lab Anim.* 1988; 22 (2): 162-5.
14. Weisbroth S, Scher S. *Trichosomoides crassicauda* infection of a commercial rat breeding colony. I. Observations on the life cycle and propagation. *Lab Anim Sci.* 1971; 21 (1): 54-61.
15. Bahrami S, Rezaei A, Alborzi A. *Trichosomoides crassicauda* infection in wistar rats. *Arch Razi Inst.* 2014; 69 (1): 63-7.
16. Tabaran F, Catoi C, Gal A, Bolfă P, Taulescu M, Nagy A, Cuc C, Borza G, Moussa R. Histopathological changes of the urinary bladder in the natural occurred infection with *Trichosomoides crassicauda* in Albino rats. *Bulletin UASVM.* 2011; 68 (1): 401.
17. Serakides R, Ribeiro A, Silva C, Santos R, Nunes V, Nascimento E. Proliferative and inflammatory changes in the urinary bladder of female rats naturally infected with *Trichosomoides crassicauda*: report of 48 cases. *Arq Bras Med Vet Zootec.* 2001; 53 (2): 1-5.
18. Thomas LJ. Studies on the life history of *Trichosomoides crassicauda* (Bellingham). *J Parasitol.* 1924; 10 (3): 105-36.
19. Chapman WH. The incidence of a nematode, *Trichosomoides crassicauda*, in the bladder of laboratory rats. treatment with nitrofurantoin and preliminary report of their influence on urinary calculi and experimental bladder tumors. *Invest Urol.* 1964; 2: 52-7.
20. Martin B. Cell replacement and differentiation in transitional epithelium: a histological and autoradiographic study of the guinea-pig bladder and ureter. *J Anat.* 1972; 112 (3): 433-55.